

THE SCAPHOID: COMPLICATIONS AND TREATMENT

D.L. FERNANDEZ

Lindenhof Hospital, Berne, Switzerland

SCAPHOID NON-UNION

Scaphoid non-unions have a known natural history (1, 2), not all are symptomatic (3), not all destabilize the carpus and symptoms are accelerated by strenuous use of the hand. The two most important factors affecting the success in gaining union are the time elapsed between initial injury and treatment, and the presence of avascular necrosis of the proximal fragment (4, 5). These parameters, as well as the presence of periscaphoid degenerative changes must be carefully evaluated as they represent major impediments to achieve a successful outcome with conventional bone grafting techniques. Herbert (6-8) classified scaphoid non-unions in four types: 1) *fibrous union* (without deformity), 2) *pseudoarthrosis* (early deformity), 3) *sclerotic pseudarthrosis* (advanced deformity), and 4) *avascular pseudarthrosis* (fragmented proximal pole). His recommendations for treatment are still valid:

- 1) *Fibrous non-unions* (or delayed union): these are stable with absent deformity or collapse, have an excellent prognosis, should all be repaired, but bone grafting may not always be necessary.
- 2) *Mobile non-unions*: are unstable, have early collapse patterns (DISI), a good prognosis and require anterior wedge grafting.
- 3) *Sclerotic non-unions*: are unstable, have moderate to marked collapse and early degenerative changes, ischaemic proximal poles, and therefore carry a fair prognosis. A reconstruction

trial is recommended according to age, occupation, and symptoms.

- 4) *Avascular non-unions*: have non reconstructable fragmented proximal poles. These have a poor prognosis, and therefore reconstruction is contra-indicated.

In general terms, the categories of reconstruction of an ununited scaphoid can be divided into: 1) an established non-union without secondary degenerative changes within the wrist in which sound union of the scaphoid is the major goal; 2) a scaphoid non-union with early degenerative changes in which establishing union of the scaphoid has to be combined with an additional procedure such as a radial styloidectomy (9), and 3) a scaphoid non-union with advanced degenerative wrist arthritis for which only a salvage procedure (that is, resection arthroplasty, partial or total wrist fusion) should be considered.

For the first category, the surgical considerations are based on the concept of stability, the location of the non-union, and the presence or absence of osteonecrosis. Stable, ununited scaphoid fractures in an anatomically acceptable position still profit from conventional inlay bone grafting (5, 10-15).

The surgical management of the unstable, angulated, or displaced non-unions located at the scaphoid waist or distal third along with intact blood supply to the proximal pole is based on gaining more anatomic intrascaphoid angles and scaphoid length. This is best accomplished with an anteriorly placed interpositional graft along with internal fixation (6, 17-22).

Anterior wedge grafting technique

It has become clear from the data in a number of publications (1-3, 7, 23-25) that ununited fractures of the scaphoid associated with displacement or angulation as well as malunited fractures will have a higher likelihood of associated osteoarthritis and impaired wrist function. In one study of Jiranek and associates (26), more than 50% of patients treated for a scaphoid non-union with a conventional inlay bone graft were found to have united with deformity. Although there was no significant subjective difference between those patients whose scaphoid healed anatomically compared to those with a malunion, there was a significant difference in the functional results between these two groups. Tsuyuguchi and associates (27) also found a statistically significant correlation between improved wrist function and improved carpal alignment following anterior wedge-shaped grafting for an established scaphoid non-union.

Unstable non-unions of the scaphoid exhibit the following deformity (based on the position of the distal fragment): a) flexion ("humpback deformity"), b) ulnar deviation (radial angulation), c) pronation (rotatory malalignment), d) shortening, and e) occasionally translation (step-off's).

Scaphoid deformity and determination of the intrascaphoid angles (28) has been thoroughly analysed with 3-spiral tomography, CT-scans (29-31). Fractures distal to the apex of the dorsal ridge usually develop a palmar type of late deformity (flexion and overhang of the distal fragment), whereas fractures of the proximal third develop a dorsal type of late deformity with dorsal slipping of the distal fragment, without carpal malalignment.

Anterior interpositional bone grafting technique is the current method of choice for unstable, deformed, and angulated non-unions located at the waist or at the distal third of the carpal scaphoid with a viable proximal fragment. Restoration of normal scaphoid length through distraction of the non-union restores the "strut" function of the radial column of the carpus, which, in turn, controls the initial carpal collapse and the associated dorsal lunate rotation (19).

Preoperative planning

To correct angular deformity and restore normal scaphoid length, the amount of resection and size of the graft needed are calculated pre-operatively by carefully tracing the radiographic findings in the AP and lateral views of the injured and of the contralateral wrists (Fig. 1). This helps us to determine the amount of carpal collapse and the normal and pathological scapholunate and lunocapitate angles for each case individually. Particularly in the unstable mobile non-unions, the pseudarthrotic gap opens in maximal ulnar deviation. An X-ray of both wrists taken in this position (Fig. 1) is very helpful for determining the amount of bone defect that has to be replaced by the interpositional bone graft in the anteroposterior plane. An X-ray of the uninjured wrist in the same position is useful to measure scaphoid length, because the scaphoid rotates to an extended position in maximal ulnar deviation. The size and form of the graft can be calculated.

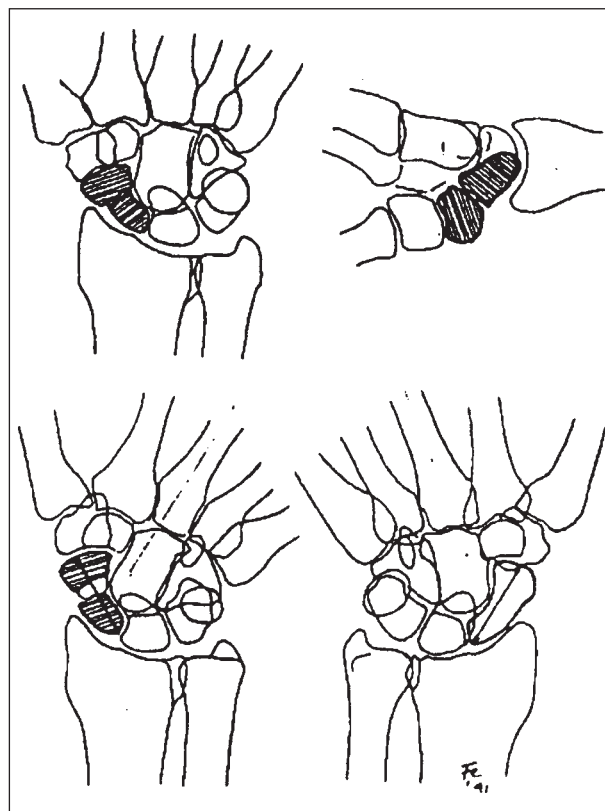


Figure 1. AP and lateral views of the injured and of the contralateral wrist.

ted in millimeters and will vary, depending on the specific deformity of each particular scaphoid non-union.

The humpback deformity can be evaluated more exactly using lateral trispiral tomograms or ct scans taken in the long axis of the scaphoid (29) and exact calculation of the defect, size, and form of the graft can be obtained with three dimensional CT imaging (30).

Surgical technique

An extended volar Russe approach is used. The capsule is incised in line with the skin incision. The capsular flaps that contain the strong radioscapohcapitate ligament are held on both sides with stay sutures to facilitate anatomic closure. Sclerotic or irregular borders of the non-union site are then resected with a small oscillating saw to offer a perfect surface contact between the graft and the scaphoid fragments. Additional cystic defects are curetted out and filled with small cancellous bone chips. The flexion deformity and shortening of the scaphoid are corrected by distracting the osteotomy on the palmar radial aspect with a small spreader clamp, or simply by hyperextending the wrist over a rolled towel. As this is done, the surgical assistant simultaneously corrects the dorsal rotation of the lunate by pushing the palmar pole towards the radius with a fine bone spike or by using a K-wire inserted through the palmar pole of the lunate to control rotation. The cortical cancellous graft is obtained from the iliac crest and shaped according to the preoperative plan and the intraoperative dimensions of the bone defect and inserted with the cortical part of the graft being oriented palmarly (Fig. 2).

If neutral lunate rotation cannot be achieved spontaneously by distracting and correcting the scaphoid deformity (irreducible DISI deformity), a fine K-wire is inserted through the palmar pole across the lunate fossa of the radius and brought out percutaneously through the dorsal aspect of the forearm, and maintained during 8 weeks post-operatively.

Finally, compression screw fixation of the scaphoid is carried out. Careful closure of the palmar capsule completes the operation, and a palmar

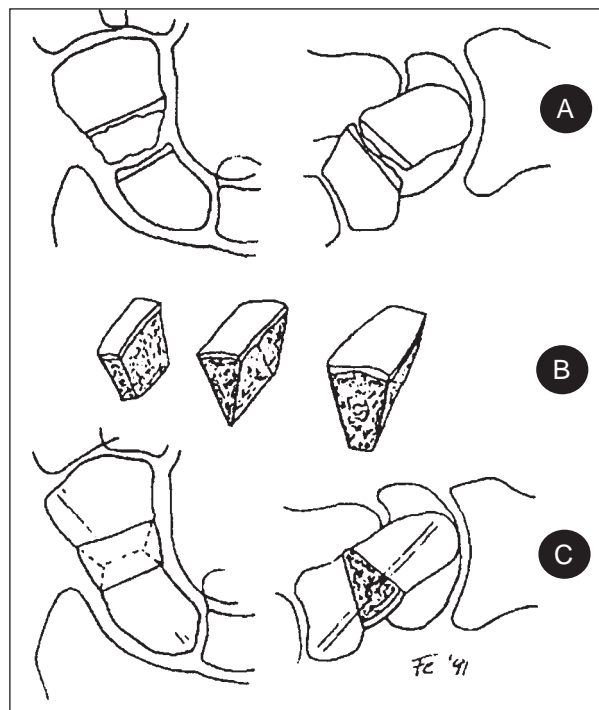


Figure 2. Preoperative planning for interpositional bone graft technique. A) Resection of sclerotic borders of non-union. B) Iliac corticocancellous bone graft with rectangular, triangular, and trapezoidal cross-section, depending on size and shape of defect. C) Final result with graft in place, correcting the "humpback deformity" and lunate rotation and showing ideal screw positioning in the AP and sagittal planes.

plaster splint that includes the thumb is applied postoperatively for 2 weeks. Wrist immobilization is discontinued at 2 weeks after the operation except in those cases, where Kirschner-wire fixation of the lunate across the radius is needed for the first 8 weeks. Should postoperative pain persist at 2 weeks, a removable plastic splint or wrist brace may be used for another 2 weeks. The patient is encouraged to use the hand for activities of daily living. However, heavy manual work and strenuous sport activities are forbidden until 8 weeks after surgery. At this time, the first radiographic control using scaphoid views is made. Our criteria to establish healing are 1) the absence of pain, 2) the radiographic evidence of bridging bony trabeculae on both sides of the interposed graft, 3) disappearance of the osteotomy lines in conventional x-rays, and 4) no signs of screw loosening.

Non-unions of the proximal pole

These fall into the category of the dorsal type of late deformity, and are seldom associated with DISI malalignment. If the fragment shows adequate vascularity (pre-operative Gadolinium enhanced MRI highly recommended), these non-unions are best managed through a dorsal surgical approach combining autogenous cancellous bone graft and a small screw subchondrally placed from proximal to distal (33).

SCAPHOID MALUNION

Although the malunited scaphoid fracture is a recognized entity that causes altered carpal kinematics and abnormal load distribution, and that may cause premature wrist arthrosis, the reported number of patients treated with early osteotomy is surprisingly small (4, 34-37). Malunion of the scaphoid is a frequent complication of conservatively treated waist and distal-third fractures, and after conventional inlay grafting procedures in which union is achieved without correcting of the deformity.

Although Amadio et al. (28) in a study of 46 fractures, found that slightly more than half the patient population had a malunited scaphoid with a higher incidence of degenerative changes than those healed in an anatomic position, the true incidence of scaphoid malunion is probably not known since not all patients are symptomatic. Impaired wrist function associated with malunited scaphoids after Russe bone grafting procedures was reported by Jiranek et al. (26), but these investigators stated that the presence of scaphoid deformity was not predictive or poor final outcome.

The classic deformity of a malunited scaphoid includes shortening, flexion in the sagittal plane, and ulnar deviation of the distal fragment in the frontal plane. Furthermore, a rotational malalignment with pronation of the distal fragment in the horizontal plane is also present (31, 38). Patients with symptomatic scaphoid malunion complain of dorsal wrist pain, particularly on forced dorsi-

flexion. Wrist extension typically is limited by the flexion component of the scaphoid deformity (7, 39). These are the patients that require a corrective osteotomy of the scaphoid.

Radiographic assessment

Comparative radiographs will show a short scaphoid, an ulnar displacement of the distal third of the scaphoid, usually overlapping the radial aspect of the capitate in the PA views. The lateral radiographs inevitably show a DISI dorsally rotated lunate with an increased radiolunate angle.

Scaphoid deformity can be further evaluated with trispiral tomograms of CT scans. This enables us to accurately measure the intrascaphoid angles (Fig. 3A).

Angular correction of the scaphoid can be planned preoperatively by subtracting the normal values of the contralateral scaphoid intrascaphoid angles from the pathological values of the injured side. For assessment of associated dorsal intercalated instability, the radiolunate and scapholunate angles should be recorded from plain radiographs. Rotational malalignment can be usually assessed and corrected intraoperatively (38).

Postoperatively a dorsoradial splint that includes the thumb is applied for 10 days. Following suture removal, the wrist is immobilized in a soft thumb spica cast for 3 weeks. Thereafter a removable wrist brace is worn until the patient feels comfortable. At 8 weeks scaphoid views and PA tomograms are used to assess union. To assess the correction of carpal alignment compared with the preoperative status, comparative radiographs of both wrists are also performed. This allows accurate measurement of the scapholunate angle, a useful indicator of associated dorsal carpal instability.

In summary it may be concluded that not all scaphoid malunions are symptomatic, assessment of deformity is standardized, surgical correction is straight forward but multiplanar including derotation of the distal fragment, and that non-union or avascular necrosis following osteotomy have not been complications in series reported to date.

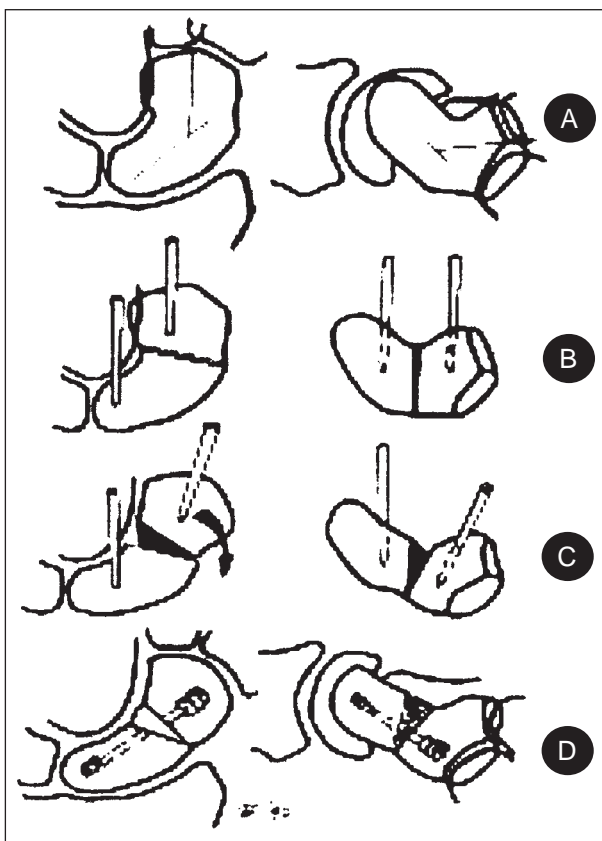


Figure 3. *Surgical technique (21, 38). A) The PA and lateral intrascaphoid angles have been measured on tracings of scaphoid views. B) Transverse osteotomy at the old fracture site. Note the parallel K-wires in both fragments which are used as joy-sticks during angular and rotational correction. C) Multiplanar correction of the deformity: the distal fragment has been extended, supinated (arrow), and radially deviated. D) Fixation with Herbert screw after insertion of the palmar and ulnar based trapezoidal bone graft.*

SCAPHOID NON-UNIONS WITH IMPAIRED VASCULARITY

Vascular impairment of the proximal segment of a scaphoid fracture can be separated into three categories. *Transient ischemia; partial or reversible necrosis; and complete, irreversible necrosis* (7). In transient ischemia, the proximal pole is temporarily deprived of its intraosseous circulation because of the fracture; the circulation is restored when the fracture unites. Transient ischemia is associated with increased radiographic density without subchondral collapse, deformity, or abnormal bone tra-

beculae. Partial or reversible avascular necrosis, as seen in some instances of non-union, reflects an increased bone density associated with a disappearance of normal cancellous bone trabeculation, deformity, and cystic changes. Complete, irreversible necrosis is characterized by the changes of partial necrosis as well as by subchondral collapse and fragmentation similar to those seen in the late stages of Preiser or Kienbeck disease. At this stage, revascularization may not be possible since fragmentation is associated with permanent structural changes of the bone matrix (40, 41). Not only is the vascular supply absent, but there is also incongruity of the joint surfaces because of post-ischemic collapse and fragmentation as well as degenerative changes of the cartilage envelope. For this reason, an operation that is done to promote union will compromise the chances for pain relief and for prevention of further collapse and of subsequent osteoarthrotic changes of the wrist. However, if the proximal fragment is ischemic but not deformed and there is no evidence of advanced periscaphoid osteoarthrosis or of established carpal collapse, it seems that a logical way to preserve the anatomical integrity of the scaphoid is to accelerate union with a revascularisation procedure.

Although there is a change that ischemic proximal poles will be revascularised with Russe inlay-grafting (42-44), the results with this method have been unpredictable, especially when the recipient bone has been completely avascular (45-47). If there is clinical and radiographic evidence of avascular necrosis or of recurrent pseudarthrosis due to instability, revascularisation may be accelerated by the use of vascularized bone grafts or vascular bundle implantation (48).

Currently vascularity of scaphoid non-unions is best assessed with Gadolinium enhanced MR imaging (49). Based on biopsy material, x-ray findings, and MR imaging, Büchler and Nagy (50) proposed a classification of avascular necrosis of the scaphoid and provided the following information: in Class I group the proximal fragment is temporarily deprived of intraosseous circulation. There is central necrosis, lipolysis, decreased signal in T1 MR images. Bony trabeculae are well preser-

ved, if immobile vascularity is restored in 3 weeks. Trabecular thickness is increased and X-ray density reflects healing of the post-ischaemic area. In Class A there is trabecular collapse, subchondral sequestrae and osteogenic activity scant or absent. Healing potential is greatly reduced due to permanent structural changes of the bone matrix. In Class 2 B motion and excessive loading lead to mechanical failure of trabeculae. There is increased osteoclastic activity, focal resorption, cystic changes, and X-ray density now due to crushed dead trabeculae. This type is commonly associated with non-union, and is common after failed scaphoid reconstruction attempts.

Based on these findings, vascularized bone grafting is currently recommended (21, 52), for:

- 1) small proximal poles;
- 2) Class 1 lesion of larger fragments with scant or absent bleeding points;
- 3) recurrent non-union (failed conventional bone grafting) that fall into the Class 2 B;
- 4) long standing non-unions.

Despite having achieved successful results with vascular bundle implantation and conventional bone grafting (48), we now utilize the Zaidenberg (53) pedicle graft based on the 1, 2 intercompartmental supraretrinacular branch of the radial artery (ICSRA), for cases that not require correction of deformity (small proximal poles) and the Mathoulin graft based on the palmar carpal artery (54), if associated correction of the humpback deformity is necessary (55, 56).

SCAPHOID NON-UNION ADVANCED COLLAPSE

The patterns of arthritis associated with a scaphoid non-union were initially identified by Watson and associates (57, 58). This condition is similar to that associated with chronic scapholunate ligament incompetence, in that the wrist has lost the structural support of the scaphoid, which normally maintains the anatomic orientation of the scaphoid and distal radius as well as the capitate within the center of rotation of the wrist.

Four stages of arthritis exist and include:

- Stage I: characterized by osteophyte formation of the radial styloid without substantial narrowing of the radius-scaphoid articulation;
- Stage II: reflecting progression of arthritis to now involve the radioscaphoid joint;
- Stage III: now involving the capitulunate articulation; and
- Stage IV: in which arthritis has involved all but the lunate-radius articulation.

The management of the stage I wrist depends on whether or not criteria exist to warrant an attempt at gaining union. If so, combined with a radial styloidectomy, the outcome will be favorable. Alternatively, if the proximal pole of the scaphoid has demonstrated significant collapse or has other poor prognostic factors for predicting success with an attempt to gain unions, a soft-tissue arthroplasty can be performed through a dorsoradial approach.

The surgical technique most used for patients with stage II arthritis include *proximal row carpectomy* and a *four-bone intercarpal arthrodesis* involving the capitate, lunate, triquetrum, and hamate in conjunction with scaphoid excisions (57-61). However, in our hands *scapho-capitate-lunate fusion* (62) *combined with styloidectomy* has produced equally adequate long term results. This operation addresses the affected joints, maintaining the integrity of the ulnar side of the carpus.

In one retrospective study involving 24 patients, Tomaino et al. (60) observed that patients treated with a proximal row carpectomy, when compared with a group who had four-corner fusions, required a shorter period of immobilization and had improved range of wrist motion. By the same token, follow-up radiographs demonstrated the development of progressive arthrosis between the capitate and radius in the patients treated with proximal row carpectomy.

When intercarpal arthritis has progressed to stage III, involving the capitate-lunate articulation, decision making focused on either an attempt to retain some wrist motion with a four-corner intercarpal fusion or performing a total wrist arthrodesis. The latter is to be considered as well for patients with stage IV involvement.

REFERENCES

1. Ruby LK, Stinson J, Belsky MR. The natural history of scaphoid non-union. A review of fifty-five cases. *J Bone Joint Surg* 1985; 67A: 428-32.
2. Mack GR, Bosse MJ, Gelberman RH, et al. The natural history of scaphoid non-union. *J Bone Joint Surg* 1984; 66A: 504-9.
3. Lindström G, Nyström A. Natural history of scaphoid non-union with special reference to asymptomatic cases. *J Hand Surg* 1992; 17B: 697-700.
4. Schuind F, Haentjens P, Van Innis F, et al. Prognostic factors in the treatment of carpal scaphoid nonunions. *J Hand Surg* 1999; 24A: 761-76.
5. Green DP. The effect of avascular necrosis on Russe bone grafting for scaphoid nonunion. *J Hand Surg* 1985; 10A: 597-605.
6. Herbert TJ, Fisher WE. Management of the fractured scaphoid using a new bone screw. *J Bone Joint Surg* 1984; 66B: 114-23.
7. Herbert TJ. The fractured scaphoid. St. Louis, Quality Medical Publishing, 1990.
8. Filan SL, Herbert TJ. Herbert screw fixation of scaphoid fractures. *J Bone Joint Surg* 1996; 78B: 519-29.
9. Mazet R Jr, Hohl M. Radial styloidectomy and styloidectomy plus bone graft in the treatment of old ununited carpal scaphoid fractures. *Ann Surg* 1960; 152: 296-306.
10. Cooney WP, Dobyns JH, Linscheid RL. Fractures of the scaphoid: a rational approach to management. *Clin Orthop* 1980; 49: 90-7.
11. Kleinert JM, Zenni EJ Jr. Nonunion of the scaphoid: review of literature and current treatment. *Orthop Rev* 1984; 13: 125-41.
12. Russe O. Fracture of the carpal navicular: diagnosis, non-operative treatment, and operative treatment. *J Bone Joint Surg* 1960; 42A: 759-68.
13. Andrews J, Miller G, Haddad R. Treatment of scaphoid nonunion by volar inlay distal radius bone graft. *J Hand Surg* 1985; 10B: 214-6.
14. Warren-Smith CD, Barton NJ. Non-union of the scaphoid: Russe graft vs Herbert screw. *J Hand Surg* 1988; 13B: 83-6.
15. Schneider LH, Aulicino P. Nonunion of the carpal scaphoid: the Russe procedure. *J Trauma* 1982; 22: 315-9.
16. Trumble TE, Clarke T, Kreder HJ. Non-union of the scaphoid: treatment with cannulated screws compared with treatment with Herbert screws. *J Bone Joint Surg* 1996; 78A: 1829-37.
17. Fernandez DL. Anterior bone grafting and conventional lag screw fixation to treat scaphoid non-unions. *J Hand Surg* 1990; 15A: 140-7.
18. Stark HH, Richard TA, Zemel NP, et al. Treatment of ununited fractures of the scaphoid by iliac bone grafts and Kirschner-wire fixation. *J Bone Joint Surg* 1988; 70A: 982-91.
19. Fernandez DL. A technique for anterior wedge-shaped grafts for scaphoid nonunions with carpal instability. *J Hand Surg* 1984; 9A: 733-7.
20. Cooney WP, Linscheid RL, Dobyns JH, et al. Scaphoid nonunion: role of anterior interpositional bone grafts. *J Hand Surg* 1988; 13A: 635-50.
21. Fernandez DL, Eggli S. Scaphoid nonunion and malunion: how to correct deformity. *Hand Clin* 2001; 17-7; 631-46.
22. Eggli S, Fernandez DL, Beck Th. Unstable scaphoid non-union: A medium-term study of anterior wedge grafting procedures. *J Hand Surg* 2002; 27B: 36-41.
23. Kaneshiro SA, Failla JM, Tashman S. Scaphoid fracture displacement with forearm rotation in a short-arm thumb spica cast. *J Hand Surg* 1999; 24A: 984-91.
24. Nakamura R, Imaeda T, Tsuge S, et al. Scaphoid non-union with DISI deformity. A survey of clinical cases with special reference to ligamentous injury. *J Hand Surg* 1991; 16A: 156-61.
25. Steiger R, Sennwald G. Late results of operated scaphoid pseudarthroses. *Handchir Mikrochir Plast Chir* 1990; 22: 152-5.
26. Jiranek WA, Ruby LK, Millender LB, et al. Long-term results after Russe bone-grafting: the effect of malunion of the scapoid. *J Bone Joint Surg* 1992; 74A: 1217-28.
27. Tsuyuguchi Y, Murase T, Hidaka N, et al. Anterior wedge-shaped bone graft for old scaphoid fractures or non-unions. *J Hand Surg* 1995; 20B: 194-200.
28. Amadio PC, Berquist TH, Smith DK, et al. Scaphoid malunion. *J Hand Surg* 1989; 14A: 679-87.
29. Sanders WE. Evaluation of the humpback scaphoid by computed tomography in the longitudinal axial plane of the scaphoid. *J Hand Surg* 1988; 13A: 182-7.
30. Belsole RJ, Hilbelink DR, Llewellyn JA, et al. Computed analysis of the pathomechanics of scaphoid waist nonunions. *J Hand Surg* 1991; 16A: 899-906.
31. Nakamura R, Imaeda T, Horii E, et al. Analysis of scaphoid fracture displacement by three-dimensional computed tomography. *J Hand Surg* 1991; 16A: 485-92.
32. Moritomo H, Viegas SF, Elder KW, et al. Scaphoid nonunions: a 3-dimensional analysis of patterns of deformity. *J Hand Surg* 2000; 25A: 520-8.
33. Retting ME, Raskin KB. Retrograde compression screw fixation of acute proximal pole scaphoid fractures. *J Hand Surg* 1999; 24A: 1206-10.

34. Barton NJ. Twenty questions about scaphoid fractures. *J Hand Surg* 1992; 17B: 289-310.
35. Birchard D, Pichora D. Experimental corrective scaphoid osteotomy for scaphoid mal-union with abnormal wrist mechanics. *J Hand Surg* 1990; 15A: 863-8.
36. Lynch NM, Linscheid RL. Corrective osteotomy for scaphoid malunion: technique and long-term follow-up evaluation. *J Hand Surg* 1997; 22A: 35-43.
37. Nakamura R, Imaeda T, Miura T. Scaphoid malunion. *J Bone Joint Surg* 1991; 73B: 134-7.
38. Fernandez DL, Martin CL, Gonzales del Pino J: Scaphoid malunion: the significance of rotational malalignment. *J Hand Surg* 1998; 23B: 771-5.
39. Burgess RC. The effect of a simulated scaphoid malunion on wrist motion. *J Hand Surg* 1987; 12A: 774-6.
40. Carter PR, Malinin TI, Abbey PA, et al. The scaphoid allograft: a new operation for treatment of the very proximal scaphoid nonunion or for the necrotic, fragmented scaphoid proximal pole. *J Hand Surg* 1989; 14A: 1-12.
41. Verdan C, Narakas A. Fractures and pseudarthrosis of the scaphoid. *Surg Clin North Am* 1968; 48: 1083-95.
42. Carrozzella JC, Stern PJ, Murdock PA: The fate of failed bone graft surgery for scaphoid nonunions. *J Hand Surg* 1989; 14A: 800-6.
43. Cooney WP III, Dobyns JH, Linscheid RL. Nonunion of the scaphoid: analysis of the results from bone grafting. *J Hand Surg* 1980; 5: 343-54.
44. Cooney WP, Linscheid RL, Dobyns JH. Scaphoid fractures. Problems associated with nonunion and avascular necrosis. *Orthop Clin North America* 1984; 15: 381-91.
45. Guimberteau JC, Panconi B. Recalcitrant non-union of the scaphoid treated with a vascularized bone graft based on the ulnar artery. *J Bone Joint Surg* 1990; 72A: 88-97.
46. Hull WJ, House JH, Gustillo RB, et al. The surgical approach and source of bone graft for symptomatic nonunion of the scaphoid. *Clin Orthop* 1976; 115: 241-7.
47. Pechlaner S, Hussl H, Knzel KH. Alternative Operationsmethode bei Kahnbeinpseudarthrosen. Prospektive Studie. *Handchirurgie* 1987; 19: 302-5.
48. Fernandez DL, Eggli S. Non-union of the scaphoid. *J Bone Joint Surg* 1995; 77A: 883-893.
49. Cerezal L, Abascal F, Canga A, et al. Usefulness of Gadolinium - Enhanced MR imaging in the evaluation of the vascularity of scaphoid nonunions. *Am J Radiology* 2000; 174: 141-9.
50. Büchler U, Nagy L. The issue of vascularity in fractures and non-union of the scaphoid. *J Hand Surg* 1995; 20B: 726-35.
51. Bishop AT. Vascularized pedicle grafts from the dorsal distal radius: design and application for carpal pathology. *Curr Prac Hand Surg* 1997: 307-13.
52. Shin AY, Sheets KK, Bishop AJ, et al. Vascularized pedicled bone graft from the distal radius. *Arch Am Acad Orthop Surg* 1999; 2: 94-106.
53. Zaidenberg C, Siebert J, Angrigiani C. A new vascularized bone graft for scaphoid non-union. *J Hand Surg* 1991; 16A: 474-8.
54. Mathoulin C, Haerle M. Vascularized bone graft from the palmar carpal artery for treatment of scaphoid nonunion. *J Hand Surg* 1998; 23B: 318-23.
55. Boyer MI, von Schroeder HP, Axelrod TS. Scaphoid nonunion with avascular necrosis of the proximal pole. *J Hand Surg* 1998; 23B: 686-90.
56. Straw RG, Davis TRC, Dias JJ. Scaphoid non-union: treatment with a pedicled vascularized bone graft based on the 1,2 intercompartmental suprapole branch of the radial artery. *J Hand Surg* 2002; 27B: 413-6.
57. Watson HK, Vallet FL. The SLAC wrist: scapholunate advanced collapse pattern of degenerative arthritis. *J Hand Surg* 1984; 9A: 358-65.
58. Watson HK, Weinzweig J, Zeppieri J. The natural progression of scaphoid instability. *Hand Clin* 1997; 13: 39-49.
59. Ashmead D, Watson HK, Damon C, et al. Scapholunate advanced collapse wrist salvage. *J Hand Surg* 1994; 19A: 741-50.
60. Tomaino MM, Miller RJ, Cole I, et al. Scapholunate advanced collapse wrist: proximal row carpectomy or limited wrist arthrodesis with scaphoid excision? *J Hand Surg* 1994; 19A: 134-42.
61. Viegas SF. Limited arthrodesis for scaphoid non-union. *J Hand Surg* 1994; 19A: 127-33.
62. Rotman MB, Manske PR, Pruitt DL, et al. Scaphocapitolunate arthrodesis. *J Hand Surg* 1993; 18A: 26-33.