

TRANSPOSITION OF THE INDEX TO THE AMPUTATED MIDDLE FINGER AT AN UNUSUAL LEVEL

F. PARMAKSIZOGLU¹, T. BEYZADEOGLU²

¹Department of Orthopaedics and Traumatology, School of Medicine, Yeditepe University, Istanbul, Turkey

²Department of Orthopaedics and Traumatology, Private Umut Hospital, Istanbul, Turkey

Trasposizione ad un livello insolito del dito indice al dito medio amputato.

SUMMARY

A 49 years old male patient had an injury in the index and middle fingers of his left hand, which was initially treated elsewhere. He had two/third of the proximal phalanx of his middle finger intact after its amputation for necrosis. An X-ray analysis of his hand detected the comminuted intraarticular fracture of the index proximal phalanx with a loss of uniformity of the metacarpophalangeal joint. An evaluation of such patient showed that the metacarpophalangeal joint of his index finger could not be salvaged and the decision of using the metacarpophalangeal joint of the middle finger stump for the restoration of the index metacarpophalangeal joint with an unusual transposition method was made. Thus the contact of this two fingers was achieved; scissoring and gap formation between the fingers were prevented through the transposition of the second digit to the third at the level of the proximal phalanges. The aesthetic and functional results were satisfactory in our patient and the available anatomic structures after injury were used efficiently. Riv Chir Mano 2003; 40: 140-144

KEY WORDS

Transposition, amputation, finger, hand

RIASSUNTO

Un paziente maschio di 49 anni ha subito una lesione all'indice e al medio della mano sinistra, inizialmente trattata in un'altra sede. È stata eseguita un'amputazione ai 2/3 della falange prossimale del terzo dito per necrosi. L'esame radiografico della mano ha dimostrato una frattura intraarticolare comminuta della falange prossimale del dito indice con perdita della morfologia dell'articolazione metacarpofalangea. L'articolazione metacarpofalangea del secondo dito non poteva essere recuperata e si è deciso di impiegare la metacarpofalangea del moncone del terzo dito per il ripristino dell'articolazione metacarpofalangea del secondo dito con un metodo insolito di trasposizione. Si è ottenuto così l'avvicinamento delle dita tra loro, dalla trasposizione del secondo dito al terzo dito a livello della falange prossimale, evitando l'effetto a forbice ed il gap. Il risultato estetico e funzionale nel nostro paziente è stato soddisfacente e le strutture anatomiche disponibili dopo la lesione sono state utilizzate in modo efficiente.

PAROLE CHIAVE

Trasposizione, amputazione, dito, mano

Arrived: 23 April 2003

Accepted: 4 June 2003

Correspondence: Dr. Fatih Parmaksizoglu, Sahil yolu sok. No: 26 Dragos – Maltepe 81530 Istanbul, Turkey - Tel. +90-532-416 85 35

Fax: +90-216-473 44 89 - E-mail: fatihparmaksiz@superonline.com

INTRODUCTION

Digital transpositions are frequently performed as a way of treatment in digital amputations with the aim to achieve a better hand function and aesthetic appearance. The contour of the hand would not be disturbed with non-functional stumps; therefore ray resection is preferred after the amputations of the second and fifth digits, whereas transposition is the preferred method after the amputations of the third and fourth digits. The fingers at the radial side would deviate to the ulnar side by the pressure of the thumb while the ulnar fingers would deviate to radial side by the contact position of the hand to the hard surfaces, if the third and forth fingers remain as stumps. The contact of the fingers to each other should be preserved and space between the fingers should be prevented so as to avoid any kind of deformities.

CASE REPORT

A 49 years old male seaman had a crush injury to the second and third digits of his left hand, which was initially treated elsewhere. The intra-articular comminuted fracture of the index proximal phalanx had been fixated with an intramedullary K-wire without any articular restoration. The comminuted fracture of the distal phalanx of the

crushed middle finger had also been fixated with another K-wire. A few days later amputation at the level of the proximal phalanx and stump revision had to be performed due to the necrosis of the middle finger (Fig. 1 A, B).

The patient was evaluated in our clinic twenty-five days after the injury. He had 2/3 of the middle finger proximal phalanx intact following amputation (Fig. 2 A, B). X-ray of the hand demonstrated the comminuted defective intraarticular fracture of the index proximal phalanx with loss of uniformity of the metacarpophalangeal joint (Fig. 3). It was detected that the metacarpophalangeal joint of the second finger could not be salvaged and it was decided to use the metacarpophalangeal joint of the middle finger stump for the restoration of the index metacarpophalangeal joint with an unusual transposition method.

Transposition of the index to the middle finger at the level of the proximal phalanges was achieved. First, ray resection of the second metacarpal with an oblique osteotomy at its base was performed. Then, the index finger distal to the damaged part of the proximal phalanx was transposed to the stump of the proximal phalanx of the third finger. Bone fixation was performed with K-wires followed by soft-tissue reconstruction. The flexor tendons and the distal part of the A2 pulley of the transposed second digit were repaired to the proximal portions of the third digit. The extensor

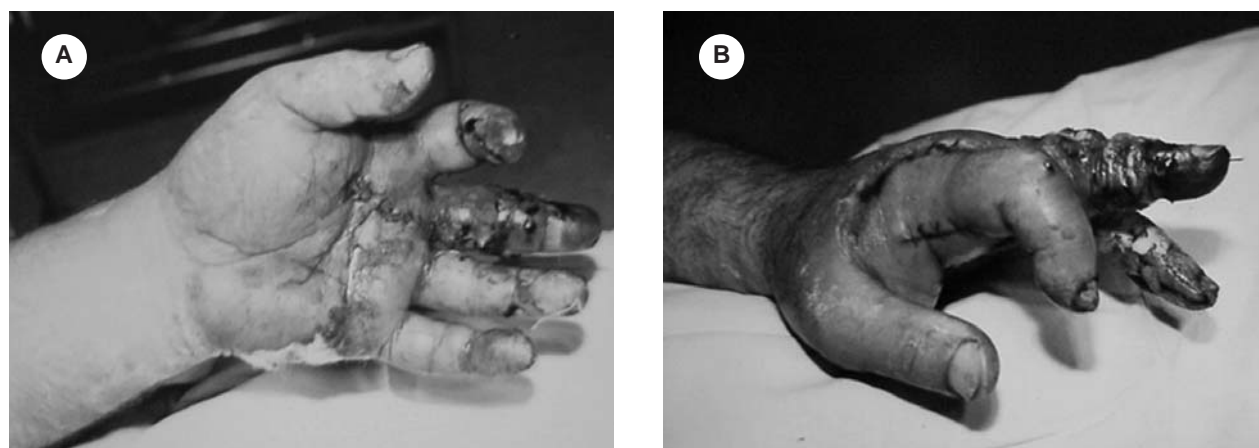


Figure 1. A, B) The view of the necrosis of the distal middle finger after the initial operation elsewhere (the photo had been taken for the reassurance company).

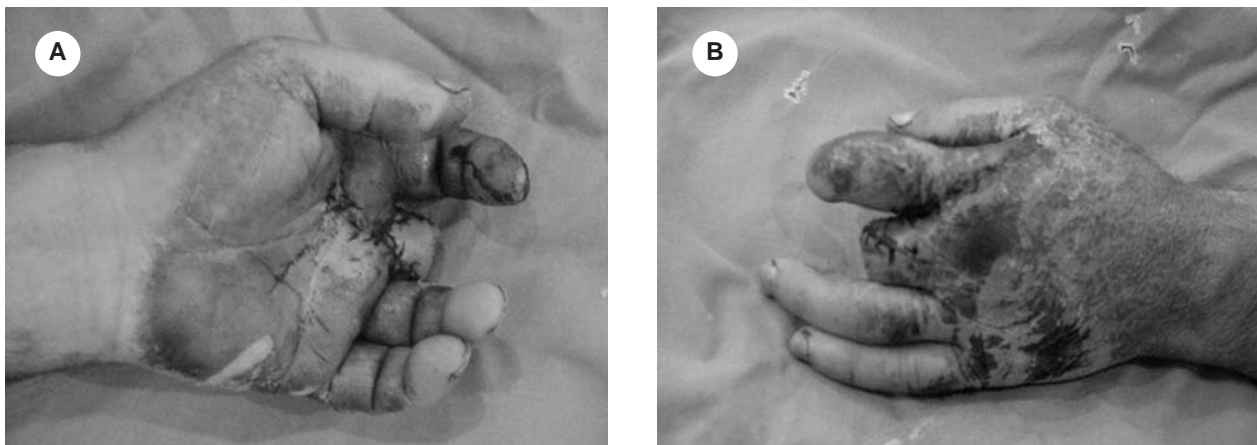


Figure 2. *A, B) The third digit had been amputated at the proximal phalanx level.*

hood and the proximal part of the extensor tendon of the third digit were reconstructed to the distal portion of the index extensor tendon (Fig. 4). Tightness of the tendons was prevented with adequate shortening of the bone. Thus, per-operatively it was clearly observed that the adjusted tendon lengths permitted the full passive extension and flexion of the transposed finger.

After bony consolidation at 8 weeks, the patient was begun an intensive physical therapy and hand rehabilitation course (Fig. 5). At the fifth month post-operatively tenolysis of the both flexor and extensor tendons was performed. The follow-up was 16 months and the patient could use his hand easily in his daily activities (Fig. 6 A-C).

DISCUSSION

The transposition of the second digit to the third in the absence of the third digit or the transposition of the fifth digit to the fourth in the absence of the fourth digit are the preferred treatment modalities for digital amputations (1, 2). By transposition, radial deviation of the fingers with the contact of the hand to the hard surfaces, and ulnar deviation of the fingers with the pressure of the thumb in pinching would be prevented. The function and strength of the palm for load carrying also improved.

It was reported that complete removal of the middle metacarpal with distal intermetacarpal liga-

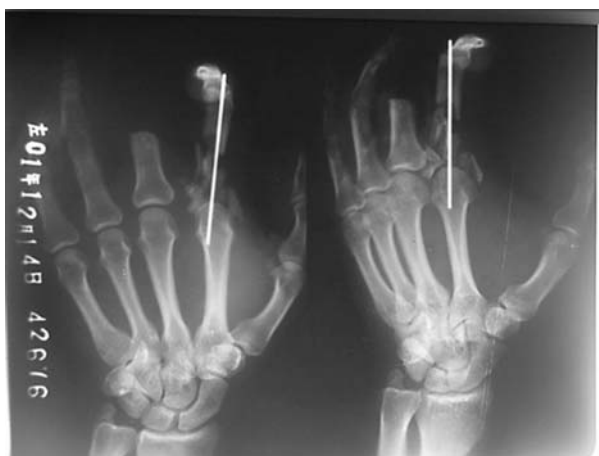

Figure 3. *The metacarpophalangeal joint of the index finger was damaged irreparably.*

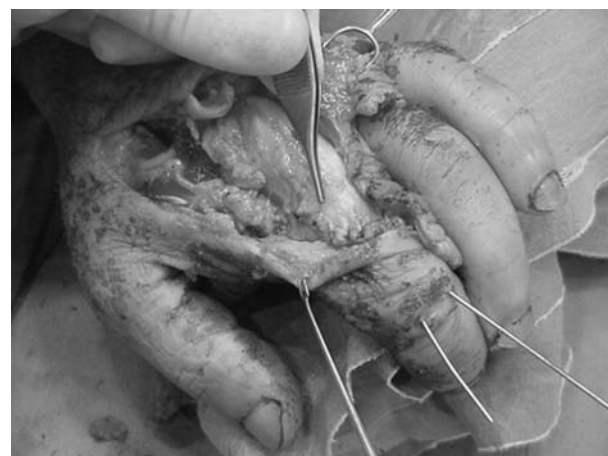

Figure 4. *The per-operative view of the reconstruction of the extensor mechanism of the transposed digit.*

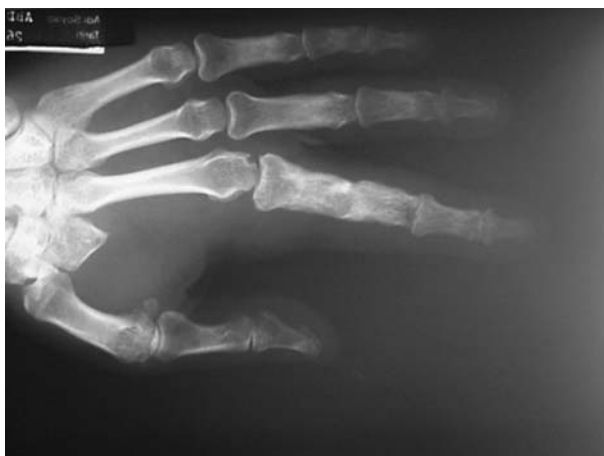

Figure 5. *X-ray of the hand at the end of the treatment.*

ments repair appears to allow the bases of the second and third metacarpals migrate together without any tendency of the fingers to scissor on flexion or to remain slightly apart (3). Transpositions are performed from the metacarpal level. After the osteotomy from the base of the metacarpal, transposition of the second metacarpal to the resected ray of the proximal third metacarpal and internal fixation with reconstruction of the distal intermetacarpal ligaments is the suggested method (1, 2). The pinch and grip recovery of the patients was found as 83.3% and 80.2% of the non-operated site, respectively that was a neglected power loss (4).

Transpositions can be used following traumatic amputation of one or both central digits or in conjunction with surgical removal of third or fifth digit involved by a malignancy or when there is congenital hypoplasia (5). Transpositions after acute injuries have better results than in late cases (6). Sometimes central ray resection is performed without any bony transposition. It was reported that satisfactory results could be achieved with reconstruction of the deep transverse metacarpal ligament after resection without transposition (7).

Metacarpophalangeal joints are the main joints of all fingers and should be protected for finger functions. In our case, metacarpophalangeal joint of the index finger was irreparable and the proximal phalanx was in good condition in its distal

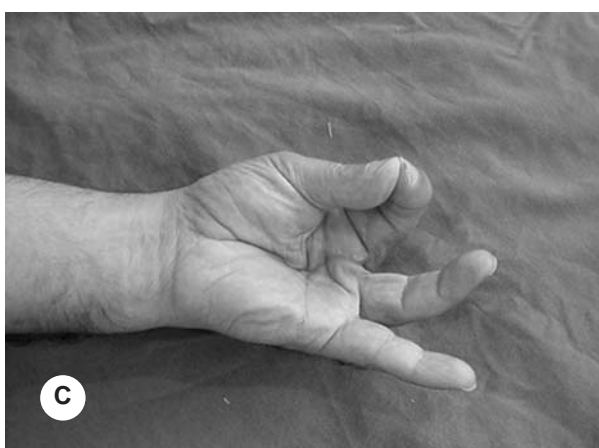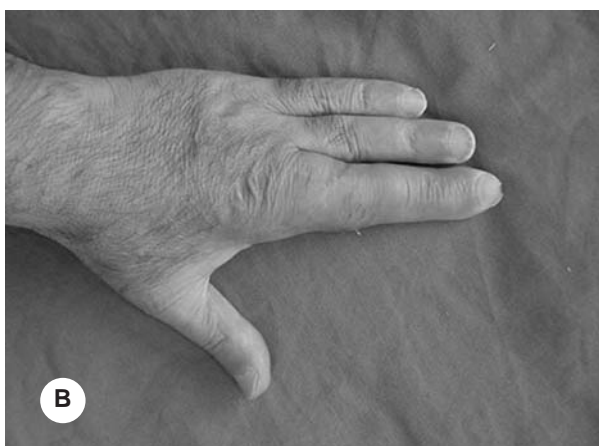

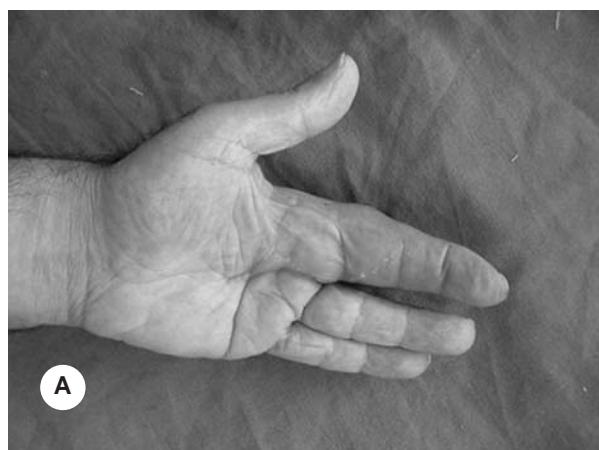
Figure 6. *A-C) The view of the patient's hand at the end of the treatment.*

half, while the middle finger had an intact proximal phalanx and metacarpophalangeal joint with good soft-tissue proximally, but had been amputated distally. The metacarpophalangeal joint of the

third digit could actively perform full range of motion. After transposition of the index finger without metacarpophalangeal joint to the middle finger with intact metacarpophalangeal joint, the contact of the fingers to each other was achieved; the scissoring and the gap between the fingers were prevented. The aesthetic and functional results were satisfactory in our patient and the available anatomic structures remained intact after injury has been utilized in an efficient way.

REFERENCES

1. Louis DS. Amputations. In: Green DP, Hotchkiss RN, Pederson WC, eds. *Green's Operative Hand Surgery*. 4th ed. Philadelphia: Churchill Livingstone; 1999: 53-98.
2. Razemon JP. Technique of digital transposition. In: *The Hand* Tubiana R., ed. Vol. 3, Philadelphia: WB Saunders Company; 1988: 1065-80.
3. Lyall H, Elliot D. Total middle ray amputation. *J Hand Surg* 1996; 21B: 675-80.
4. Colen L, Bunkis J, Gordon L, Waltan R. Functional assessment of ray for central digital loss. *J Hand Surg* 1985; 10A: 232-7.
5. Posner MA. Ray transposition for central digital loss. *J Hand Surg* 1979; 4A: 242-57.
6. Hanel DP, Lederman ES. Index transposition after resection of the long finger ray. *J Hand Surg* 1993; 18A: 271-7.
7. Steichen JB, Idler RS. Results of central ray resection without bony transposition. *J Hand Surg* 1986; 11A: 466-74.