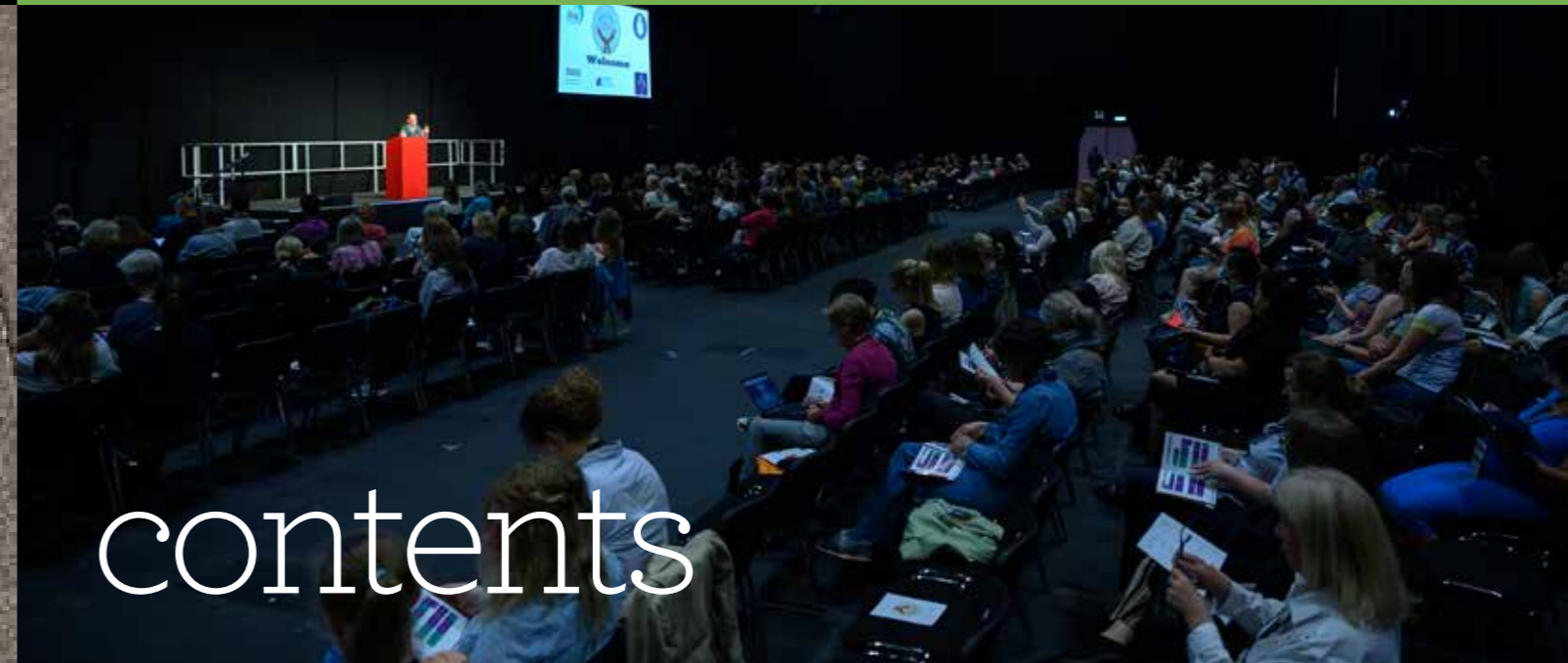

ezine ifssh

CONNECTING OUR GLOBAL HAND SURGERY FAMILY

HAND THERAPY THE RELATIVE MOTION FLEXION ORTHOISIS IN THE MANAGEMENT OF FINGER FLEXOR TENDON REPAIRS: AN UPDATE





contents



4 EDITORIAL

IFSSH Charter Perspective
- Ulrich Mennen

5 PRESIDENT'S MESSAGE

- Daniel Nagle

6 SECRETARY-GENERAL REPORT

- David Warwick

10 IFSSH EXCO ANNOUNCEMENT

Upcoming bylaws changes

11 FINAL REPORT IFSSH CONGRESS

18 PIONEER PROFILES

- Adalbert Ibrahim Kapandji
- Wladyslaw Manikowski

20 HAND THERAPY

- The relative motion flexion orthosis in the management of finger flexor tendon repairs:
An update
- Julianne W Howell
- Melissa J Hirth
- IFSHT Newsletter

27 ART

"Tre gratier"
- Istvan Lisztes

28 SCIENTIFIC CONTRIBUTION

Cortical plasticity - what we learn beyond hand surgery - an overview
- Jörg Bahm

32 SHARE SECTION

Lessons learned from 25 years of replantation surgery
- Olivier Delaere
- Patrick Suttor

38 MEMBER SOCIETY NEWS

- Korean Society for Surgery of the Hand
- Belgian Society for Surgery of the Hand
- Peruvian Association of Hand Surgery and Microsurgery
- Austrian Society for Hand Surgery
- Ecuadorian Society for Surgery of the Hand
- Australian Society for Surgery of the Hand
- Mexican Society for Hand Surgery
- Canadian Association for Hand Surgery
- Brazilian Society for Surgery of the Hand
- Association of Chinese-Speaking Hand Surgeons United

51 UPCOMING EVENTS

Perspective on the IFSSH Charter

It may be prudent to remind ourselves from time to time about the aim of the IFSSH.

The Bylaws (Article III, Section 1, Members) state that membership of the IFSSH is granted to any group of individuals (Societies or Clubs for surgery of the hand) whose members have a major interest in surgery of the hand.

The main purposes of the IFSSH are:


- to coordinate the activities by maintaining liaison between the various Societies.
- to promote the free and full exchange of knowledge among the constituent organizations
- to improve and widen the opportunities for study and observation in the various countries
- to establish and recommend the adoption of certain standards of nomenclature, classification and standards of evaluation and treatment
- to promote a bibliography of world literature on surgery of the hand
- to disseminate knowledge through publications and scientific meetings and to enhance the study and practice of surgery of the hand
- to improve the education and research in hand surgery at all professional levels
- to take an interest in the socio-economic impact of disorders of the hand
- to further the availability of hand surgery throughout the world
- to further the cooperation between hand surgery and other related professionals
- to encourage the cooperation of all members to advance the principles and practice of hand surgery of all members throughout the world

through organized participation in all areas of specialty

We as Hand Surgeons who have a major interest in hand surgery may not always remember that globally the majority of hand conditions are managed by general medical practitioners, medical officers, nurses, therapists and other related medical professionals, and not Hand Surgery Specialists.

Our main task as members of the IFSSH in the first place therefore, should be to teach and inform these primary health care professionals on the acceptable and practical ways in dealing with everyday hand cases. To become a Hand Surgeon is a privilege, and to train Hand Surgeons is rewarding, but we must share our knowledge with those who are in the frontline how to do the basic management correctly in order to minimise complications and maximise outcomes. Most people use their hands to earn their living, and most time lost from work injuries is from hand and arm trauma.

Basic hand surgery should be taught as part of primary health care.



Sincere regards,
Ulrich Mennen
Editor

President's message

My Dear Colleagues,

I am humbled and honoured to stand here before you as the 20th President of the International Federation of Societies for Surgery of the Hand. I thank the Member Societies of the Federation for their confidence and support. I look forward to working with the Delegates and newly expanded Executive Committee, as we continue to refine the Federation's governance and expand the opportunities for educational sponsorship.

I must thank Dr. Garcia Elias for his friendship and the kind and thoughtful leadership he has provided during these tumultuous times.

I look forward to seeing you all in Washington DC in 2025.

Thank you.
Dan.



Daniel Nagle
President: IFSSH

ezone
ifssh
CONNECTING OUR GLOBAL HAND SURGERY FAMILY

IFSSH DISCLAIMER:

The IFSSH ezine is the official mouthpiece of the International Federation of Societies for Surgery of the Hand. The IFSSH does not endorse the commercial advertising in this publication, nor the content or views of the contributors to the publication. Subscription to the IFSSH ezine is free of charge and the ezine is distributed on a quarterly basis.

Should you be interested to advertise in this publication, please contact the Editor: ezine@ifssh.info

IFSSH EZINE EDITORIAL TEAM:

EDITOR:

Professor Ulrich Mennen
Past President: IFSSH

DEPUTY EDITOR:

Professor Michael Tonkin
Past President: IFSSH

GRAPHIC DESIGNER:

Tamrin Hansen
www.foxydesign.co.za

TO SUBSCRIBE GO TO:

www.ifssh.info
administration@ifssh.info

Secretary General Report



Message from the Outgoing Secretary-General:

S. Raja Sabapathy

Performing the role of the Secretary-General in an International organization can be a great experience. For me it was enjoyable as I was working with a great team led by President Marc Garcia-Elias and our administrative secretary, Belinda Smith, who is extraordinarily efficient. It was eventful as we made a good overhaul of the By-laws governing the IFSSH to make it more vibrant. It was satisfying as we introduced the concept of the Mid-term Course in Hand Surgery which will also help to make the IFSSH more visible. Most importantly, many countries came out of their travel restrictions of the pandemic, and we had a wonderful in-person IFSSH congress in London. On a personal note, it was a pleasure to work with the local organizing committee led by David Shewring, Jonathan Hobby and Wee Lam and congress organizers Asszisztencia.

I hand over the baton to David Warwick who I am sure will help steer the IFSSH to greater heights in its quest to promote Hand Surgery worldwide.

Message from the Incoming Secretary-General:

David Warwick

It is a privilege to take over the baton of Secretary General from Raja Sabapathy. I would like to thank him for all his contributions so far and for all his future involvement as President Elect and then President. Having worked as the Historian for the past 6 years, I have seen the remarkable support provided by Belinda Smith, our Administrative Secretary.

Without her institutional knowledge, dedication and efficiency, the role of Secretary-General would be impossible. As it would be without the dedication and contribution of the entire Executive Committee. I look forward to working with the Executive Committee - our President Dan Nagle, the new Communications Director Jin Bo Tang, President Elect Raja Sabapathy, Past President Marc Garcia-Elias and of course our expanded pool of Members-at-Large and new Nominating Committee - to maintain and grow the wonderful role that the IFSSH assumes in the world of hand surgery.

15th IFSSH Congress, London: June 6-10, 2022

The 15th triennial IFSSH Congress was a spectacular week of reconnecting with colleagues in person in London. Over 3600 hand surgeons and therapists from 89 countries participated in the congress, experiencing a sophisticated scientific programme and enjoying the social events.

2022 IFSSH Pioneers of Hand Surgery

The tradition of inducting IFSSH Pioneers of Hand Surgery continued at the Opening Ceremony, with 28 surgeons honoured:

Peter Amadio

- American Association for Hand Surgery

Ronaldo Jorge Azze

- Brazilian Society for Surgery of the Hand

Jacques Baudet

- French Society for Surgery of the Hand

Duke Whan Chung

- Korean Society for Surgery of the Hand

Abraham Cuperman Donskoy

- Colombian Association for Surgery of the Hand

José Mauricio de Moraes Carmo

- Brazilian Society for Surgery of the Hand

David Elliot

- British Society for Surgery of the Hand

Marybeth Ezaki

- American Society for Surgery of the Hand

Alexandru Georgescu

- Romanian Society for Surgery of the Hand

Rolf Habenicht

- German Society for Surgery of the Hand

Leiv M. Hove

- Norwegian Society for Surgery of the Hand

William B. Kleinman

- American Society for Surgery of the Hand

Simon Kay

- British Society for Surgery of the Hand

Bhaskaranand Kumar

- Indian Society for Surgery of the Hand

Susan E. Mackinnon

- American Society for Surgery of the Hand

Murray Hugh Matthewson

- British Society for Surgery of the Hand

Duncan Angus McGrouther

- British Society for Surgery of the Hand; Singapore Society for Hand Surgery

A. Lee Osterman

- American Association for Hand Surgery; American Society for Surgery of the Hand

Timo Raatikainen

- Finnish Society for Surgery of the Hand

Yolanda Restrepo De Marriaga

- Colombian Association for Surgery of the Hand

Robert Russell

- American Association for Hand Surgery

Francois Schernberg

- French Society for Surgery of the Hand

Beat R. Simmen

- Swiss Society of Hand Surgery

Michael A. Tonkin

- Australian Hand Surgery Society

Allen Van Beek

- American Association for Hand Surgery

Catherine Vlastou

- Hellenic Society for Surgery of the Hand

Batia Yaffe

- Israeli Society for Surgery of the Hand

Fok-Chuan Yong

- Singapore Society for Hand Surgery

The IFSSH extends its sincere gratitude to all Pioneers for their contributions to the field of hand surgery.

2022 IFSSH Delegates' Council Meeting

The annual IFSSH Delegates' Council Meeting was held on Wednesday 8 June with a number of important decisions reached. As described in the revised Bylaws, the Executive and Nominating Committees have been expanded to allow for greater participation, regional representation and increased transparency. We thank all who submitted nominations and congratulate those who were appointed:

Incoming IFSSH Executive Committee

Past-President (by succession): **Marc Garcia-Elias**

President (by succession): **Daniel Nagle**

President-Elect (by succession): **Raja Sabapathy**

Secretary-General: **David Warwick**

Communications Director: **Jin Bo Tang**

Members-at-Large:

- Asia-Pacific: **Gregory Bain**

- North America: **Jorge Clifton Correa**

- South America: **Aida Garcia Gomez**

- Europe and Africa (x2): **Francisco del Piñal and**

David Shewring

Incoming IFSSH Nominating Committee

Past-President (automatic appointment to committee):

Marc Garcia-Elias (Chair)

President (automatic appointment to committee):

Daniel Nagle

Members-at-Large: **Ilse Degreef and Peter Amadio**

2024 IFSSH Mid-Term Course

The Delegates' Council also selected the host Society for the inaugural IFSSH Mid-Term Course. Four competitive bids were presented by the Australian Hand Surgery Society, Bolivian Association of Hand Surgery, Ecuadorian Hand Surgery Society, and Thai Society for Surgery of the Hand. The Ecuadorian Hand Surgery Society was successful and will host the course in February 2024. This is a great achievement for a recently established Society and we look forward to supporting their progress as they plan this course.

2028 IFSSH Triennial Congress

The 2028 IFSSH Triennial Congress Host was also selected. After informative and entertaining bids, the Singapore Hand Surgery Society was selected over the Association of Chinese-Speaking Hand Surgeons United. Congratulations to all involved in the preparation of the Singaporean bid.

Further general business matters will be detailed in subsequent newsletters.

Future Meetings

A detailed list of national and regional hand surgery meetings is available on the IFSSH website. The triennial IFSSH Congresses are as follows:

1st IFSSH Mid-Term Course in Hand Surgery

– Ecuador
14– 17 February, 2024

XVIth IFSSH – XIIIth IFSHT Congress

– Washington D.C., USA
23- 28 March, 2025

XVIIth IFSSH – IXth IFSHT Congress

– Singapore
23– 27 October, 2028 (TBC)

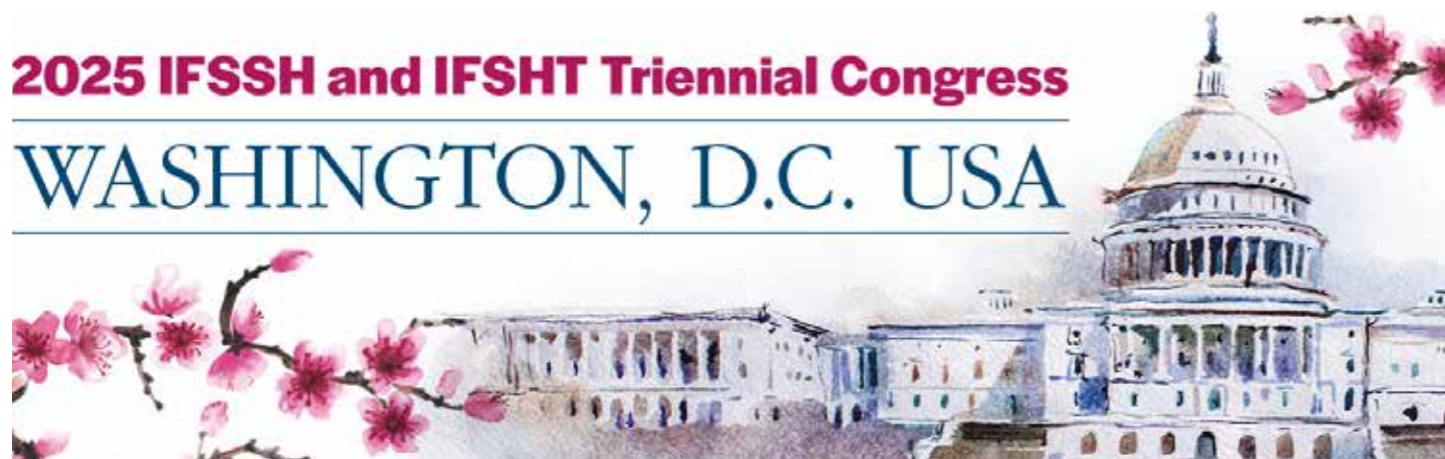With very best wishes



David Warwick
Secretary-General, IFSSH
Email: secretary@ifssh.info
Web: www.ifssh.info
Twitter/Instagram: @IFSSHHand

2025 IFSSH and IFSHT Triennial Congress

WASHINGTON, D.C. USA



Upcoming bylaws changes



The International Federation of Societies for Surgery of the Hand revised its bylaws in 2020 to address the preservation of institutional memory, the excessive time spent on the Executive Committee, to improve opportunities for Societies to participate in the governance of the IFSSH, to improve the transparency of the Executive Committee nomination process and improve global representation on the Executive Committee.

The 2020 bylaws have been successful in achieving these goals. Indeed, the global representation on the Executive Committee has expanded from one Member-at-large to five Members-at-large including one Member-at-large each from the North America/Central America/Caribbean region, the South America region and the Asia-Pacific region. Two Members-at-large now sit on the Executive Committee from the Europe/Africa region given the large number of Societies in that region. The nomination process is now more transparent thanks to the addition of two Members-at-large selected by the Delegates' Council.

The Secretary General-elect position has been eliminated and eventually the President-elect position will be eliminated to decrease from fifteen years to nine years the time spent in the Presidential line.

Embedded in the 2020 bylaws were provisions for an eventual move to a biennial IFSSH Congress. However, the Delegates' Council elected to preserve the triennial congress. The proposed 2022 bylaw changes you will be asked to ratify are housekeeping changes needed to restore the Executive Committee terms to three years to be consistent with a triennial congress.

In addition to this, the amended 2022 bylaws will contain more detailed description of the Federation membership requirements previously included in the Policies and Procedures.

It is the Executive Committee's hope to have these bylaw changes in your hands for review and voting by early September. The ElectionBuddy system used in 2020 will once again be used for the bylaws change process.

The Executive Committee sincerely appreciates your support and participation in the IFSSH.

Daniel J Nagle MD, FAAOS, FACS
President: International Federation of Societies for Surgery of the Hand.



IFSSH, IFSHT & FESSH COMBINED CONGRESS LONDON 2022

6-10 June 2022 ExCeL, London, UK

The combined IFSSH, IFSHT and FESSH conference took place at the ExCeL Conference Centre in London during the second week of June 2022. Despite several significant obstacles during the years leading up to the conference, we consider that it was a success.

Linked to the congress was a new feature for IFSSH: a programme of observational fellowships. During the two weeks prior to the congress thirty-two fellows appointed in open competition from thirty countries visited 18 centres around the UK. At the end of the two weeks the fellows travelled to London for the Jubilee weekend. A teaching programme was organised at the newly refurbished Royal College of Surgeons and there was a tour of the sights of London, prior to the start of the Congress.

The "Elizabeth Line" was finished just in time for the congress and opened to the public just a few days before. This provided a high-speed connection from London Heathrow airport, via Paddington station, to a station at the entrance of ExCeL, making traveling across London significantly easier. Stencils of the logo on the pavement led delegates from the station to the entrance of ExCeL.....



After an "Educational afternoon", organised by FESSH at the ExCel on Monday, we had the opening ceremony. There were addresses from Marc Garcia-Elias (IFSSH), Nicola Goldsmith (IFSHT), Daniel Herren (FESSH) and Jonathan Hobby (BSSH), before Raja Sabapathy introduced the Pioneers of Hand Surgery, with twenty-eight pioneers being honoured. Marc Garcia-Elias, IFSSH President, then gave a moving tribute to the "Unknown Surgeon", with an accompanying book. Following the closure of the ceremony we were entertained by the "Evolve Shadow Show", a stylised history of the earth in silhouettes, with a bespoke hand surgery theme. At the after-party in the exhibition area, we were entertained by the Ben Harker jazz trio. There was a tangible aura of joy around the venue, with many people meeting for the first time since the disruption of COVID.

Assisztencia, assisted by the BSSH office team delivered a fantastic event. The conference was attended by 3,073 on site and a further 632 online, with a total of 3,765 registrations from 89 countries around the globe. We ran a hybrid programme for those in countries unable to attend, mainly for Asian countries where on-going travel restrictions prevented many from attending. There was a broadcast of a selection of the content followed by an online discussion, starting at 06.00 each day. On site there were over 1,700 presentations with 960 free papers, all of which are now available as on-line videos on the congress website.

The theme of the core series of instructional course lectures was "Tendon Disorders of the Hand and Wrist". A series of plenary lectures was accompanied by a book edited by me, Dean Boyce and Grey Giddins, published by Thieme and included in the full registration fee. This book represents the current "state of the art" thinking and practice in discipline of tendon surgery and we were privileged to have chapter contributions from leaders in the field, from all corners of the globe. Although practice inevitably evolves, we hope that this volume will serve as a useful guide and definitive reference for years to come.

There was a fantastic program team led by Jonathan Hobby and Wee Lam with a comprehensive programme of instructional sessions and symposia. The Swanson lecture was given by Professor Tim Davis from Nottingham and featured his work on scaphoid fractures.

The Presidential Lecture was given by Professor Gus McGrouther from Singapore with a discussion of current concepts on hand infection. Professor David Ring from the USA gave the BSSH Douglas Lamb Lecture on the influence of psychological factors on outcomes in hand surgery. The British Association of Hand Therapists, led by Christy Fowler, Helen Buchanan, Fiona Sandford, Lisa Newington and Donna Kennedy organised a fantastic therapy programme.



The Presidential dinner was held at the Barber Surgeons on Tuesday evening with transport to and from the venue in traditional London Buses, which had been requisitioned. On Wednesday there was a lively "Pub Night" organised by the therapists at the Revolution Bar which was very well attended. On Thursday, we had the Gala dinner at the Old Billingsgate. Guests arrived by water taxi from the ExCeL and disembarked near the Tower of London, for a champagne reception on the terrace overlooking the Thames and Tower Bridge. After dinner the "MIB Band" filled the dance floor, with a free bar until the early hours of the morning. The dinner was attended by 900 people.

The logo proved to be a surprise hit, with a large wooden version of it at the entrance to the exhibition area. Each time I walked past it there were groups of people having photos taken with it, which was very gratifying.



At the IFSSH delegates meeting, the right to host the IFSSH congress in 2028 was won by a very well organised bid from Singapore, led by Mark Puhaingran. Congratulations to the Singapore team and we look forward very much to that.

The well attended closing ceremony took place on Friday lunchtime, with a handover from the outgoing IFSSH president Marc Garcia-Elias to the incoming president Dan Nagle. We wish him luck for his tenure.

We are very much looking to the next meeting in Washington, which we are sure will be a great event.

Meanwhile, here are some memories from London.....<https://youtu.be/zJUA7PI3rks>

We are pleased that it seemed to go well. It was certainly worth every scrap of all the effort through the years.



We certainly enjoyed it.

We hope you did too....

Best wishes

David Shewring

Consultant Hand Surgeon, University Hospital of Wales, Cardiff
Chair, Organising Committee IFSSH/IFSHT/FESSH London 2022





www.ifssh.info

August 2022



*IFSSH/IFSHT Congress
in London, June 2022”
(Photos by Simon Callaghan)*

IFSSH, IFSHT & FESSH
COMBINED CONGRESS LONDON 2022
6-10 June 2022, ExCel, London, UK



www.schinfo

August 20 22



Adalbert Ibrahim Kapandji

17/04/1928 - 07/01/2019



Adalbert Ibrahim Kapandji was born on 17 April 1928 in Paris, France. He descended from a Turkish-Greek family who settled in Paris. After completing his basic medical studies at the Faculty of Medicine in Paris (1951-1956), he worked in various surgical

departments in Paris specialising as a general and orthopaedic surgeon from 1956 to 1960.

Kapandji earned his 'Doctor of Medicine' in 1960. He then worked as an Assistant Surgeon at the Hospital La Pitié-Salpêtrière and the Hospital Broussais until 1964. During this time he was also Chief of Clinics of the Faculty of Medicine in Paris. His interest in anatomy and function was kindled by his Surgeon father Mehmet Ibrahim Kapandji and his maternal grandfather Adalbert Chevalier, a marine engineer. His mother Robert Jeanne was a painter from whom he must have inherited his drawing skills. Kapandji was also Professor of Anatomy at the Nurses School of Paris Hospitals and the Physiotherapy School in Necker Hospital from 1959-1965, and from 1968-1970 at the Physiotherapy Staff School at Bois-Larris.

Adalbert Kapandji then established in 1965 and managed the private orthopaedic and hand surgery clinic, named the "Clinique de l'Yvette" in Longjumeau in the south of Paris, and worked there until his retirement in 2001.

Amongst many other publications, Kapandji is especially known for his major work on functional anatomy. "The Physiology of the Joints" Volume 1 (Upper Limb) and Volume 2 (Lower Limb) (English translation, Churchill Livingstone, New York, 1970), first appeared in French in 1963. These books have been translated into 11 languages. The illustrations are done by him. His exceptional drawing talent is well represented in yet another of his books: "Dessins de Mains" (Maloine, Paris 1988). In 1936 his father Mehmet and Louis Sauvé separately popularised the so called Kapandji-Sauvé procedure on the distal end of the ulna. Adalbert modified the procedure in 1986 by adding a second screw to fix the ulnar head to the radius.

Kapandji was President of the French Society for Surgery of the Hand (1987-1988), and was Honorary Member of numerous international Hand Surgery Societies.

Adalbert was married to Lydie Richard, one of his erstwhile surgical assistants, and they have a daughter Martine and a son Thierry, both medical doctors. His hobbies included photography, poem writing, travel and diving. He died aged 90 on 7 January 2019.

The title "Pioneer of Hand Surgery" was bestowed on Adalbert Ibrahim Kapandji at the Tenth Congress of the International Federation of Societies in Sydney on 11 March 2007.

Wladyslaw Manikowski

b. 28/09/1937



Wladyslaw Manikowski was born on 28 September 1937 in Vilnius, Poland. After completing secondary school education in 1955 in Poznan, he began his medical studies at the University of Poznan and graduated as a doctor in 1962. Following his internship, he worked another year in the

Rehabilitation Clinic of the Medical Faculty, before starting his training in Orthopaedics and Traumatology in 1964. In 1967 Manikowski started a further qualification in Rehabilitation of the Musculo-skeletal System. He then became an academic teacher in 1970 in the newly created Hand Surgery Clinic of the Institute of Orthopaedics and Rehabilitation of the Medical University in Poznan. He successfully defended his PhD theses in 1975 based on his research into disorders of the blood and nerve supply in patients with Dupuytren's Contracture, and then became Assistant Professor in the same year. In 1981 he was appointed Head of the Hand Clinic, followed with additional duties as Deputy Director of the Institute of Orthopaedics and Rehabilitation in 1983.

Manikowski earned a second doctoral degree (DSc) in 1988 based on his research on the reconstruction of damaged flexor tendons. In May 1989 he was appointed Associate Professor. Ten years later in 1996 he also became Associate Professor in the Academy of Music in Poznan! He became full Professor in 1999. Prof. Manikowski was also appointed Vice Dean of the

University of Poznan from 1996 to 2002 and thereafter Dean for two terms. During his tenure as Chief of Hand Surgery, he established the Laboratory of Experimental Microsurgery and introduced microsurgery as part of the hand surgery curriculum.

Prof. Manikowski supervised 18 doctoral and 9 post-doctoral theses, published over 200 papers and 18 book chapters, organised numerous courses and meetings, was Editor-in-Chief of the Polish edition of "Current Orthopaedics" from 1992-1997, as well as Deputy Editor of the Polish Journal of Orthopaedics. Manikowski was co-founder of the Polish Society for Surgery of the Hand and its President for two terms (1997-2001). He was also a two term President of the Polish Society of Orthopaedics and served on various medical boards.

For his pioneering research and academic contribution Manikowski was honoured with numerous awards, amongst others the Knight's Cross of the Order of Polonia Restituta, the Golden Cross of Merit, the Honorary Badge of the City of Poznan, the Badge of Merit for the Development of the Poznan Province, the Badge for Exemplary Work in Health Service, and the Golden Badge of Merit for the Development of Polish Fencing. Even after his retirement, he stayed on as teacher and consultant in the Departments of Orthopaedics and Hand Surgery. Wladyslaw is married to his wife, Magdalena, a pharmacist, and they have two sons.

At the Tenth Congress of the International Federation of Societies for Surgery of the Hand which was held in Sydney, Australia in March 2007, Prof. Wladyslaw Manikowski was honoured as a "Pioneer of Hand Surgery"

The relative motion flexion orthosis

IN THE MANAGEMENT OF FINGER FLEXOR TENDON REPAIRS: AN UPDATE

The relative motion extension (RME) approach has become the primary rehabilitation approach implemented by hand therapists following extensor tendon repair in zones V-VI.^(1,2) Safe early active motion (EAM) makes use of the 'quadriga effect' that results from positioning the repaired tendon metacarpophalangeal joint (MCPJ) in greater extension compared to that of the MCPJs of the uninjured digits.⁽³⁾

Safety of the RME/EAM approach has been validated biomechanically⁽⁴⁾ and clinically.^(3,5-11) Comparatively, return to function was earlier than immobilization⁽⁶⁾ or palmar blocking orthoses⁽⁷⁾ and improved patient satisfaction⁽⁷⁾.

Newer to the literature is the application of relative motion flexion (RMF) orthoses to manage zones I-II flexor digitorum profundus (FDP) tendon repairs (Figure 1a,b,c). This article offers anatomical rationale, biomechanical proof of the concept, a clinical outcomes summary, and guidelines for use of the RMF orthosis/EAM approach.

Anatomical rationale / Proof of concept

For this application of the relative motion concept⁽²⁰⁾, the quadriga effect is imposed on the FDP by positioning the involved digit's MCPJ(s) in relatively more flexion (Figure 2). Relying on the fact that the FDP is a single muscle shared by multiple tendons which serve as the primary motor for interphalangeal joint (IPJ) finger flexion.⁽²¹⁾




Figure 1a. Relative motion flexion splint for left long finger.

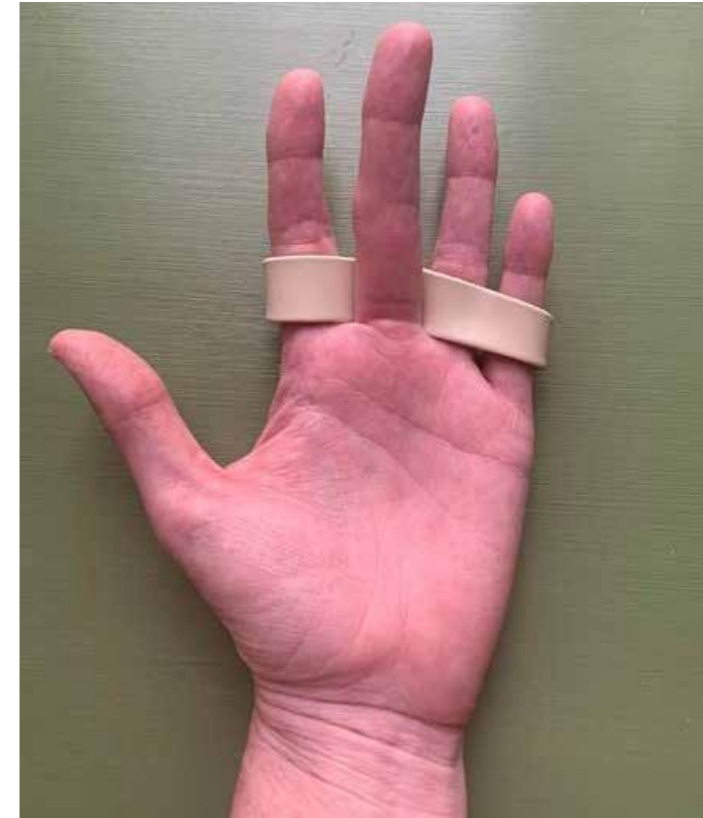

Figure 1b. Relative motion flexion splint with all fingers in extension. Long finger MCP joint in relative flexion.

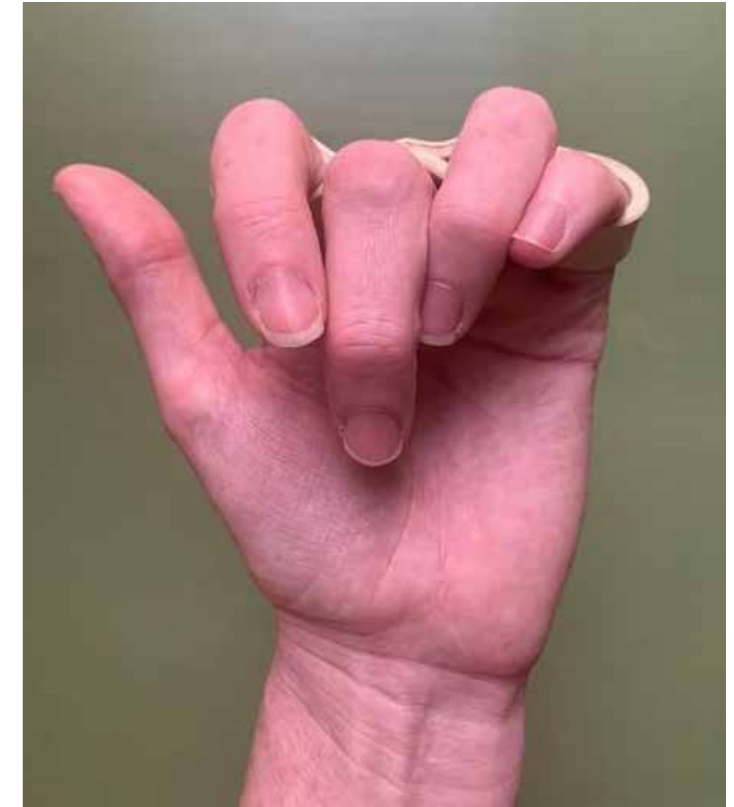

Figure 1c. Relative motion splint with all fingers in flexion. Long finger MCP joint in relative flexion.

A biomechanical 'proof of concept' cadaver study examined intact and repaired zone III FDP tendons repaired with 6-0 nylon interrupted sutures both in and out of the RMF orthosis.⁽²²⁾ In addition to a RMF orthosis, a dorsal-based forearm orthosis positioned the wrist in 30° extension and MCPJs in 50° flexion during full finger motion loading.⁽²²⁾ For tendons protected with the RMF orthosis, elongation was less than 2mm, whereas repaired tendons not protected by the RMF orthosis gapped.⁽²²⁾

The safest wrist position and relative angle of MCPJ flexion is unknown. Experimentally, in normal hands passive tension imposed by the long extensor tendons during finger flexion is the least when the wrist is in 45° extension with the MCPJs flexed compared to a neutral or flexed wrist, implying that in these positions, less force is needed for active finger flexion.⁽²³⁾

Another study measured the change in finger flexion force and linear finger flexion when a 'differential splint' (a.k.a. RMF orthosis) and neutral wrist position were used.⁽²⁴⁾ Within the 'differential splint' the involved MCPJ was put in 15, 30, or 45° more flexion than the uninvolved MCPJs, which were kept in 30° greater MCPJ flexion. The flexion forces measured at the imposed differential MCPJ angles of 30 and 45° (actually, 60 and 75° MCPJ flexion) of the long, ring and small finger decreased the most, and with index flexion force affected the least.⁽²⁴⁾ The greatest loss of linear finger flexion or tendon excursion was at the differential MCPJ angle of 45° (actually 75° MCPJ flexion) with loss of flexion greatest to least being, ring, long, small, and index finger.⁽²⁴⁾

The "work of flexion (WOF)" or "energy needed to flex the digits" (25, p18) is an important consideration after flexor tendon repair.

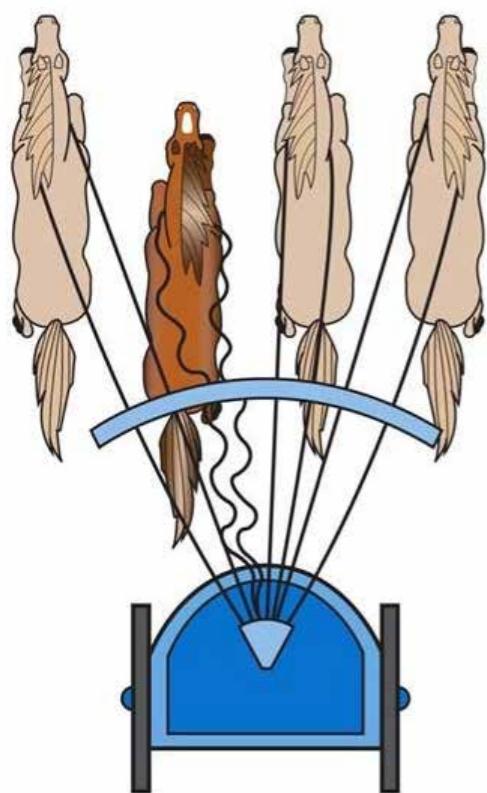


Figure 2. Chariot analogy for concept of relative motion flexion. The dark horse is the injured digit positioned in relative MCP joint flexion. In this illustration the chariot reins that are on slack represent the FDP tendon on which the 'quadriga effect' has been imposed. (©2018 KW Design. For permission to use, contact Katie Wright of Design:Wright.design.illustration.com)

The two previous studies were included as a reminder to clinicians contemplating use of the RMF orthosis to be mindful of the WOF when considering wrist and MCPJ position as each influence passive tension of long extensor and intrinsic muscles, respectively.

Secondly, generalising from the last abovementioned study, the soundest initial RMF orthosis position for the involved finger may be somewhere between 60° and 75° of MCPJ flexion while maintaining 30° MCPJ flexion differential in the non-involved digits; and when the involved finger is the index, 75° MCPJ flexion may be best. Additional research is needed to determine this.

Published outcomes summary

A 10-patient case series provides the first (and only to-date) published data on RMF orthoses for FDP zones I-II flexor tendon 4-strand repairs.⁽²⁰⁾ The initial three cases wore a dorsal wrist-hand-finger blocking orthosis (wrist in 0-20 flexion) with the RMF orthosis, whilst the remaining seven wore a 0-20 wrist extension orthosis with the RMF orthosis.⁽²⁰⁾ For all the RMF orthosis MCPJ flexion differential was 30-40°. For the first three weeks post-surgery both orthoses were worn full time (exception hand hygiene), with advice given to avoid strenuous operated hand lifting/squeezing. Patients were encouraged to move their fingers actively as allowed by the RMF orthosis and undertake light activities.⁽²⁰⁾

Specific exercises were passive composite IPJ flexion and passive IPJ extension to neutral with the MCPJ flexed.⁽²⁰⁾ At 3 weeks post-surgery the RMF orthosis was continued full time whilst the dorsal block or wrist orthosis was worn only for sleep or 'at risk' activities until week 6 when it was discontinued; full time wear of the RMF orthosis continued until 8-10 weeks post-surgery at which time all restrictions on hand use were lifted.⁽²⁰⁾ There were no tendon ruptures, secondary surgeries, or PIPJ contractures with similar mobility and functional outcomes as other EAM studies.⁽²⁰⁾

Practical advantages mentioned included the RMF orthosis/EAM approach simplicity, and the ability to permit active finger motion and functional hand use.⁽²⁰⁾

Clinical insights

Advancement in surgical procedures (eg. multi-strand core repair, excision of FDS slip and pulley venting) coupled with stronger low resistance suture materials have permitted hand surgeons to better tailor FDP tendon repairs. Similarly, therapists have many postoperative orthotic options for delivering EAM to best suit each patient's needs. The RMF orthosis/EAM approach appears to be another tool in the therapist's toolbox.

When the RMF approach is selected, thoughtful prescription of exercises both in and out of the orthosis, and proper advisement on functional hand use, especially during the initial 3-4 weeks post repair is needed. Our experience is that the orthosis imposed quadriga effect may overprotect the repair, i.e., limit FDP excursion. As a result, implementation of EAM exercises with the RMF orthosis removed is essential.

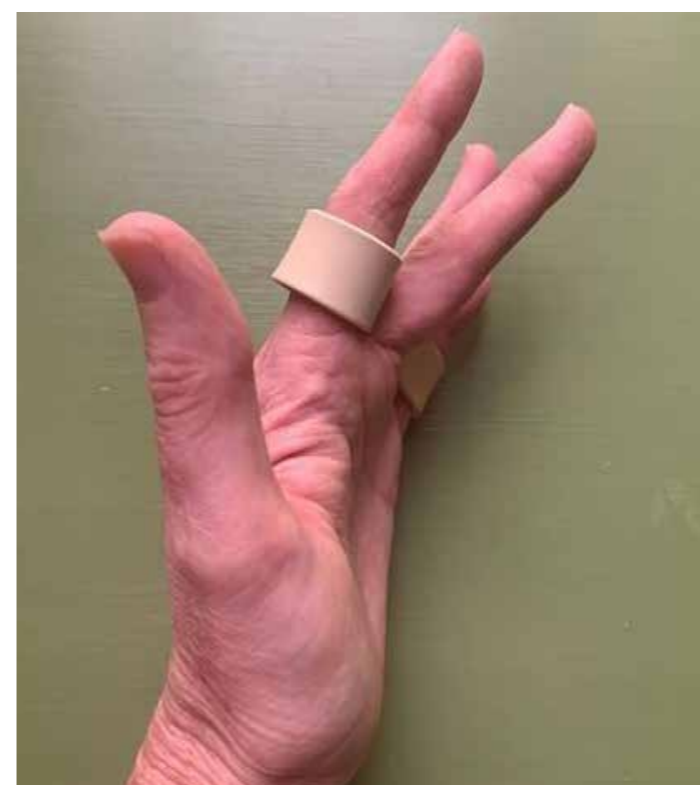

Figure 3. Relative motion flexion splint long finger in the final position as suggested by the authors for splint weaning. Note the minimum (15-20°) difference in relative flexion between the MCP joint

If the Wide-awake Local Anaesthesia No Tourniquet (WALANT) technique is used by the surgeon, knowing the MCPJ flexion differential that allowed safe excursion of the repair is useful information for planning the postoperative program. If WALANT is not used, observation and patient feedback are the therapist's best tools. Just as with other EAM flexor repair postoperative approaches, emphasis on passive IPJ motion and oedema control support safe advancement into active exercises in/out of the RMF

orthosis. As functional activities can vary between cultures, it is helpful to describe activities you prefer your patient avoid for different postoperative phases.

As an example, for the first 3 postoperative weeks while both the RMF and the wrist orthoses are being worn is to 'avoid lifting objects heavier than a tub of butter'. Equally as important is to advise patients on what they can do while wearing both orthoses, such as 'use your hand to brush your teeth'. Keeping in mind that weaning from the RMF orthosis will vary depending on the demands patients placed on their hands. One way to progress the program after the third postoperative week is to decrease flexion of the involved MCPJ while maintaining the 30° MCPJ differential. For example, if the initial flexion of the involved digit's MCPJ was 75°, the next progression would be to 60°, then later to 30°. While preserving the flexion differential with the non-involved MCP joints, initially at 60°, progressing to 30° and finally to neutral. Remember that index FDP repairs may need to be managed more conservatively (Figure 3).

Points to consider when implementing a RMF orthosis and therapy program:

- Include PROM (all digits) within the RMF orthosis. When deemed safe (patient-dependent), removing the orthosis for PROM is an option
- In and out of the RMF orthosis, encourage active initiation of finger flexion with the DIPJ first to maximize FDS/FDP differential glide (26) and focus on recovering full active PIPJ flexion (especially for zone I repairs and after FDS slip excision)⁽²⁰⁾
- Promote active PIPJ extension exercises in the RMF orthosis. If by 3 weeks postoperatively full active PIPJ extension is limited, consider adding passive stretching, or add a night IPJ extension orthosis in combination with the RMF orthosis
- Discharge of the RMF orthosis is patient/surgeon/therapist dependent, the cohort in the Henry and Howell study was discharged from all protection between 8-10 weeks postoperatively⁽²⁰⁾

Future directions and summary

The use of the RMF orthosis/EAM approach after FDP zones I-II repair has been newly introduced as a postoperative rehabilitation management choice and compares favourably to other EAM approaches.

⁽²⁰⁾ To determine the efficacy of the RMF approach in the management of finger flexor tendons, larger prospective cohorts or RCTs are required.

References:

- Hirth MJ, Howell JW, Brown T, O'Brien L. Relative motion extension management of zones V and VI extensor tendon repairs: Does international practice align with the current evidence? *Journal of hand therapy : official journal of the American Society of Hand Therapists*. Available online 9th March 2020.
- Hirth MJ, Howell JW, Feehan LM, Brown T, O'Brien L. Postoperative hand therapy management of zones V and VI extensor tendon repairs of the fingers: An international inquiry of current practice. *Journal of hand therapy : official journal of the American Society of Hand Therapists*. Available online 9th March 2020.
- Howell JW, Merritt WH, Robinson SJ. Immediate controlled active motion following zone 4-7 extensor tendon repair. *Journal of Hand Therapy*. 2005;18(2):182-90.
- Sharma JV, Liang NJ, Owen JR, Wayne JS, Isaacs JE. Analysis of relative motion splint in the treatment of zone VI extensor tendon injuries. *The Journal of hand surgery*. 2006;31(7):1118-22.
- Altobelli GG, Conneely S, Haufler C, Walsh M, Ruchelsman DE. Outcomes of digital zone IV and V and thumb zone TI to TIV extensor tendon repairs using a running interlocking horizontal mattress technique. *The Journal of hand surgery*. 2013;38(6):1079-83.
- Burns MC, Derby B, Neumeister MW. Wyndell merritt immediate controlled active motion (ICAM) protocol following extensor tendon repairs in zone IV-VII: review of literature, orthosis design, and case study-a multimedia article. *Hand*. 2013;8(1):17-22.
- Collocott SJF, Kelly E, Foster M, Myhr H, Wang A, Ellis RF. A randomized clinical trial comparing early active motion programs: Earlier hand function, TAM, and orthotic satisfaction with a relative motion extension program for zones V and VI extensor tendon repairs. *Journal of hand therapy : official journal of the American Society of Hand Therapists*. 2020.
- Hirth MJ, Bennett K, Mah E, Farrow HC, Cavallo AV, Ritz M, et al. Early return to work and improved range of motion with modified relative motion splinting: a retrospective comparison with immobilization splinting for zones V and VI extensor tendon repairs. *Hand Therapy*. 2011;16(4):86-94.
- Svens B, Ames E, Burford K, Caplash Y. Relative active motion programs following extensor tendon repair: A pilot study using a prospective cohort and evaluating outcomes following orthotic interventions. *Journal of Hand Therapy*. 2015;1(28):11-9.
- Cesim OB, Ayhan E, Bas CE, Oksuz C. Use of relative motion splint in extensor mechanism repairs: a retrospective case series. *Hand Surg Rehabil*. 2020.
- Mottay N, Govender P, Mpanza D. The use of the ICAM Splint Programme in Zone IV to VII Extensor Tendon Repairs: Patient outcomes and clinician experiences in a specialised hand unit in SA. *South African Journal of Occupational Therapy* 2020;50(2):23-34.
- Merritt WH. Surgical Demonstration: Extensor Mechanism with Anatomical Concept of a Ring Splint for Zone VI Extensor Tendon Repairs. 26th Annual American Society of Hand Therapists (ASHT) meeting; Hollywood, CA2003.
- Howell JW, Peck F. Rehabilitation of flexor and extensor tendon injuries in the hand: current updates. *Injury*. 2013;44(3):397-402.
- Merritt WH. Relative motion splint: active motion after extensor tendon injury and repair. *The Journal of hand surgery*. 2014;39(6):1187-94.
- Merritt WH, Howell JW. Relative Motion Concepts: Applied to Hand Therapy Management of Finger Extensor Tendon Zones III-VII Repairs, Acute and Chronic Boutonniere Deformity and Sagittal Band Injury. In: Skirven TM, Osterman AL, Fedorczyk J, Amadio P, Feldscher SB, Shin EK, editors. *Rehabilitation of the Hand and Upper Extremity*: Elsevier; 2020. p. 1496-510.
- Howell JW. Therapist's Corner - Relative motion flexion. *American Association for Hand Surgery, Hand Association News*, December. 2016.
- Merritt WH, Jarrell K. A Paradigm Shift in Managing Acute and Chronic Boutonniere Deformity: Anatomic Rationale and Early Clinical Results for the Relative Motion Concept Permitting Immediate Active Motion and Hand Use. *Annals of plastic surgery*. 2020;84(3S Suppl 2):S141-S50.
- Hirth MJ, Howell JW, O'Brien L. Two case reports- Use of relative motion orthoses to manage extensor tendon zones III and IV and sagittal band injuries in adjacent fingers. *Journal of hand therapy : official journal of the American Society of Hand Therapists*. 2017;30(4):546-57.
- Johnson C, Swanson M, Manolopoulos K. A case report: Treatment of a zone III extensor tendon injury using a single relative motion with dorsal hood orthosis and a modified short arc motion protocol. *Journal of hand therapy : official journal of the American Society of Hand Therapists*. 2019.
- Henry SL, Howell JW. Use of a relative motion flexion orthosis for postoperative management of zone I/II flexor digitorum profundus repair: A retrospective consecutive case series. *Journal of hand therapy : official journal of the American Society of Hand Therapists*. 2020;33(3):296-304.
- Brand PW. Mechanics of individual muscles at individual joints. In: Klein EA, editor. *Clinical Mechanics of the Hand*. St Louis, Missouri: CV Mosby Company; 1985. p. 192-309.
- Chung B, Chiu DTW, Thanik V. Relative Motion Flexion Splinting for Flexor Tendon Lacerations: Proof of Concept. *Hand*. 2019;14(2):193-6.
- Savage R. The influence of wrist position on the minimum force required for active movement of the interphalangeal joints. *Journal of hand surgery*.1988;13(3):262-8.
- Savage R, Pritchard MG, Thomas M, Newcombe RG. Differential splintage for flexor tendon rehabilitation: an experimental study of its effect on finger flexion strength. *Journal of hand surgery*. 2005;30(2):168-74.
- Amadio PC. Tendon nutrition and healing. In: Tang JB, Amadio PC, Guimberteau JC, Chang J, editors. *Tendon surgery of the hand*. Philadelphia, PA: Elsevier Saunders; 2012. p. 16-23.
- Peck FH, Roe AE, Ng CY, Duff C, McGrouther DA, Lees VC. The Manchester short splint: A change to splinting practice in the rehabilitation of zone II flexor tendon repairs. *Hand Therapy*. 2014;9(2):47-53.



JULIANNE W HOWELL,

Self-employed consultant, 1715 River Ridge, Saint Joseph, MI USA 49085
julianne0525@gmail.com

MELISSA J HIRTH,

Senior Occupational Therapist, Austin Health, Studley Road, Heidelberg, VIC, Australia 3084 & Malvern Hand Therapy, 253 Wattletree Road, Malvern, VIC, Australia 3144
melissa.hirth@austin.org.au
(left is Julianne Howell and right is Melissa Hirth)



IFSHT August 2022

IFSHT NEWSLETTER



We proudly reveal our new logo for REACH! The winner of the REACH logo competition was announced at the IFSHT Executive Committee meeting at Congress in London in June. Well done to Michele Yuen from Australia.

We are now preparing a special edition of the next issue of REACH which will exclusively report on highlights from the IFSSH-IFSHT joint Congress in June.

If you missed the last issue, you can read it here: <https://ifsht.org/publications/reach-newsletter-issue-1-2/> The publication aims to collate Research, Education, Achievement and Clinicians in Hand and upper limb therapy around the world. All previous issues are archived on the IFSHT website.

We call on hand and upper limb therapy clinicians and researchers to submit any contributions for consideration to informationofficer@ifsht.org.



IFSSH, IFSHT & FESSH Combined Congress - London, 6-10 June 2022 and the announcement of our next host

The IFSSH, IFSHT & FESSH Combined Congress was a tremendous success with peers connecting once again face to face and also virtually for the first time. Outgoing IFSHT President, Nicola Goldsmith, closed the IFSHT ceremony by thanking all and welcoming in the 2022-25 Executive Committee: Peggy Boineau (new IFSHT President) and Stacey Doyon, Susan de Klerk, Marie Eason Klatt and Liz Ward.

The Silent Auction was yet again a success raising \$8,326. Money raised will support therapists to attend the congress in 2025.

It was also announced at the Closing Ceremony that the the 2028 joint IFSSH-IFSHT Congress will be in Singapore. Next, in 2025, our host will be Washington, USA, with Aviva Wolff taking on the role as the host country Scientific Committee Co-Chair.



Look out for the link to the London Congress special edition of REACH in the next IFSSH ezine!



Art Exhibit #17

“Tre gratier”

Identical triplets expressing kindness, care and love with their rotated arms and hands.

Sculptor: Istvan Lisztes
Cast bronz. 185 cm high. 1997.
Rikshospitalet, Oslo, Norway

Cortical plasticity

WHAT WE LEARN BEYOND HAND SURGERY - AN OVERVIEW

Cortical plasticity is a fascinating concept, describing our brain cortex's capacity to learn and adapt continuously. We all know of Penfield's homunculus and its imaged cortical representation of the various body parts in the sensory and motor cortex and their relative importance by their topography, size and density.

Göran Lundborg's interesting explanations and exquisite illustrations about the processes which happen when sensory or motor nerves get injured or transected help us to understand how the brain copes with peripheral nerve damage. The represented area is "shattered" or lost, but some suboptimal restitution does happen as nerve regeneration takes place (Lundborg 2005). Body parts (like the fingers) have adjacent topographic representative areas (like the face) and we explain changes in sensation and motor control referring to and using this relationship in our endeavor to restore function.

These adaptive processes based on neurophysiological learning and memory processes have been discovered and described so well by Nobel Prize winner neuroscientist Eric Kandel. He did most of his studies on the neurophysiology of memory in marine mollusks (*Aplysia californica*) which only have twenty thousand neurons, some of them as large as 1 mm. in diameter. In his textbook on neuroscience, first published in 1981, and in an extended autobiography telling of his life and scientific career, he describes the molecular and genetic changes associated with short and long term memory and more specifically the different learning forms of habituation, sensitization and conditioning.

His books are a fascinating life story and are recommended for every interested scientist and physician.

Years before, the American neurologist Frank Wilson wrote an amazing comparative study about the hand in human evolution: "How Its Use Shapes the Brain, Language, and Human Culture" (Wilson 1999).

Cortical plasticity thus may be understood on a molecular, cellular and structural tissue level, involving physiological and pathological processes directed by brain activity and peripheral input. Motor and sensory controls are more complex than merely efferent and afferent signals or impulses. It is a dynamic process to optimize integrated bodily functions.

As we as surgeons understand more and more of the neurological processes and how to gain more function after nerve injury, and deal with neuropathic pain, nerve transfers of all sorts are being developed.

Nerve transfers bring healthy donor fascicles onto sensory or motor targets which were denervated by previous peripheral or central nerve injury, illness or tumors. This technique was described over a hundred years ago in 1913, by Alfred Stoffel, but only started to be popularized in the 1990s. It was also realized that healthy nerves do not only regenerate into other disconnected nerves (end-to-end and end-to-side augmentation), but that intact axons also have the ability to 'sprout' laterally into recipient nerves (end-to-side connection).

Non-human primate experiments on the Chacma baboon (*Papio ursinus*) have shown that nerve regeneration and new growth does indeed take place in the higher animal (Mennen 1998). This was followed by a large clinical end-to-side nerve suture series on peripheral radial, median and ulnar nerves (Mennen 1998). One of the first and most used motor nerve transfers (end-to-end) today is the "Oberlin transfer" which re-neurotises the biceps and / or brachialis muscle by redundant motor fascicles coming from the unaffected median and /or ulnar nerve (Teboul et al. 2004). After the nerve transfer, the new relevant motor area in the cortex related to the motor donor is re-wired for the new function (Anastakis et al. 2008, Socolovsky et al. 2017).

Meanwhile, their use is progressively extended from peripheral nerve injury cases to medullar trauma (para- and tetraplegia) or infection (acute myelitis transversa) and even central nerve conditions like stroke (spastic hemiplegia) and spasticity (contralateral root C7 transfer which decreases the hypertonia by the ipsilateral C7 de-connection and adds controllable new motor input by the other healthy C7, Zheng et al. 2018). It is interesting to imagine that in cases of upper limb spasticity, the surgical reduction of motor input known as hyponeurotisation or hyperselective neurotomy initially described by Georgio Brunelli, and refined by Leclercq et al. (2021) may be extended to motor nerve transfers from adjacent but healthy, non spastic donors, which are regulated by voluntarily controllable cortical areas.

The more extended use of contralateral nerve transfers (mostly the 'dispensable' C7 root) teaches us that the cortical re-organization may overcome laterality concerns. Furthermore, proximal upper limb tasks, which is a frequent parallel and simultaneous bilateral activation eg. lifting of heavy objects, involves bilateral shoulder and biceps activation. Muscles like the intercostals or diaphragm not directly involved in these bilateral movements muscles may successfully be used to reanimate elbow flexion power using a nerve transfer onto the motor nerves to brachialis and biceps muscle (Malesy et al. 2003).

These surgical techniques, based on a growing knowledge of the brain cortical reorganization,

has already extended to totally different fields of reconstructive surgery, like urology (neurogenic bladder, Agarwal et al. 2020) or ophthalmology (corneal resensibilisation, Catopano et al. 2019).

We successfully started to treat children with upper limb arthrogryposis using nerve transfers to reanimate elbow flexion and shoulder lateral rotation (Bahm et al. 2013).

Rehabilitation usually forms a very important and essential part in cortical re-

organization, not only for motor rehabilitation, but also in regaining the sensory and nociceptive pathways. The well-established mirror therapy and graded motor imagery (Moseley 2004, Strauss et al. 2021) are very useful in the treatment of neuropathic pain and CRPS. Motor rehabilitation in adults mostly needs time and an exercise program.

“
Cortical plasticity
may be understood
on a molecular,
cellular and
structural tissue
level
”

The motor function of the donor area (like finger flexion in an Oberlin transfer, breathing or coughing when the intercostal nerves have been transferred) must be specifically addressed to start biceps activity, which will need a parallel trigger training for months, before the targeted movement may be addressed separately (active elbow flexion becoming addressable even with extended fingers). Motor nerve transfers in children however, seldom need specific targeted therapy, as children are able with some months' delay to self-learn the newly gained function. This applies for classic motor nerve transfers in the upper limb, like the Oberlin or Somsak transfer. Intercostal nerve transfers aimed to reanimate elbow flexion and extension often work well with little therapy.

Although much basic knowledge is available (Moucha et al. 2006), rehabilitation techniques need to be better integrated in training programs after functional reconstructive surgery.

Brain cortical plasticity may explain why some of our nerve surgery techniques work, but much research is still needed to understand how this process can be improved. The challenging concept of brain plasticity can also be applied to all higher cerebral functions, including the specific mental states like coma or near-death-experiences, which would lead to more insights. (Lane and Laureys 2020).

Understanding these concepts better will provide more indications and surgical solutions to conditions otherwise left untreated or neglected. It is therefore not only important to refine our microsurgical and rehabilitation techniques, but also to participate in frequent discussions with colleagues internationally.

These discussions and new ideas should involve colleagues of other disciplines which would be to the benefit of all to understand this exciting and mysterious medical phenomenon. It is an ongoing process which reveals new discoveries and makes this a fascinating journey!

References

- Agarwal P, Parihar V, Kukrele RR, Kumar A, Sharma D. Anatomical feasibility of anastomosing intercostal nerves (D10&D11) and subcostal nerve (D12) to S2 ventral root and lumbar plexus for management of bladder function after spinal cord injury. *J Clin Orthop Trauma*. 2020 Sep-Oct;11(5):900-904. doi: 10.1016/j.jcot.2019.12.018. Epub 2020 Jan 2. PMID: 32879578; PMCID: PMC7452297.
- Anastakis DJ, Malessy MJ, Chen R, Davis KD, Mikulis D. Cortical plasticity following nerve transfer in the upper extremity. *Hand Clin*. 2008 Nov;24(4):425-44, vi-vii. doi: 10.1016/j.hcl.2008.04.005. PMID: 18928891.
- Bahm J. Arguments for a neuroorthopaedic strategy in upper limb arthrogyrosis. *J Brachial Plex Peripher Nerve Inj*. 2013 Oct 17;8(1):9. doi: 10.1186/1749-7221-8-9. PMID: 24135288; PMCID: PMC3953705.
- Catapano J, Fung SSM, Halliday W, Jobst C, Cheyne D, Ho ES, Zuker RM, Borschel GH, Ali A. Treatment of neurotrophic keratopathy with minimally invasive corneal neurotisation: long-term clinical outcomes and evidence of corneal reinnervation. *Br J Ophthalmol*. 2019 Dec;103(12):1724-1731. doi: 10.1136/bjophthalmol-2018-313042. Epub 2019 Feb 15. PMID: 30770356.
- Kandel ER, Schwartz JH, Jessell TM. *Principles of Neural Science*. Elsevier 1981
- Kandel ER. In Search of Memory- The Emergence of a New Science of Mind. 2007
- Lane R. Steven Laureys: a clinical focus on consciousness research. *Lancet*. 2020 Nov 28;396(10264):1719. doi: 10.1016/S0140-6736(20)32477-6. PMID: 33248489.
- Leclercq C, Perruisseau-Carrier A, Gras M, Panciera P, Fulchignoni C, Fulchignoni M. Hyperselective neurectomy for the treatment of upper limb spasticity in adults and children: a prospective study. *J Hand Surg Eur Vol*. 2021 Sep;46(7):708-716. doi: 10.1177/17531934211027499. Epub 2021 Jul 13. PMID: 34256619.
- Lundborg G Nerve Injury And Repair: Regeneration, Reconstruction And Cortical Remodeling. Churchill Livingstone 2005
- Malessy MJ, Bakker D, Dekker AJ, Van Duk JG, Thomeer RT. Functional magnetic resonance imaging and control over the biceps muscle after intercostal-musculocutaneous nerve transfer. *J Neurosurg*. 2003 Feb;98(2):261-8. doi: 10.3171/jns.2003.98.2.0261. PMID: 12593609.
- Mennen U. "End-to-side Nerve Suture in the Primate (Chacma Baboon)". *Hand Surgery*, Vol.3, No. 1, June 1998, p1-6.
- Mennen U. "End-to-side Nerve Suture in the Human Patient". *Hand Surgery*, Vol 3, No. 1, June 1998 p7-15.
- Moucha R, Kilgard MP. Cortical plasticity and rehabilitation. *Prog Brain Res*. 2006;157:111-122. doi: 10.1016/s0079-6123(06)57007-4. PMID: 17167905.
- Moseley GL. Graded motor imagery is effective for long-standing complex regional pain syndrome: a randomised controlled trial. *Pain*. 2004 Mar;108(1-2):192-8. doi: 10.1016/j.pain.2004.01.006. PMID: 15109523.
- Socolovsky M, Malessy M, Lopez D, Guedes F, Flores L. Current concepts in plasticity and nerve transfers: relationship between surgical techniques and outcomes. *Neurosurg Focus*. 2017 Mar;42(3):E13. doi: 10.3171/2016.12.FOCUS16431. PMID: 28245665.
- Strauss S, Barby S, Härtner J, Pfannmöller JP, Neumann N, Moseley GL, Lotze M. Graded motor imagery modifies movement pain, cortical excitability and sensorimotor function in complex regional pain syndrome. *Brain Commun*. 2021 Sep 25;3(4):fcab216. doi: 10.1093/braincomms/fcab216. PMID: 34661105; PMCID: PMC8514858.

- Teboul F, Kakkar R, Ameer N, Beaulieu JY, Oberlin C. Transfer of fascicles from the ulnar nerve to the nerve to the biceps in the treatment of upper brachial plexus palsy. *J Bone Joint Surg Am*. 2004 Jul;86(7):1485-90. doi: 10.2106/00004623-200407000-00018. PMID: 15252097.
- Wilson FR *The Hand: How Its Use Shapes the Brain, Language, and Human Culture* 1999
- Zheng MX, Hua XY, Feng JT, Li T, Lu YC, Shen YD, Cao XH, Zhao NQ, Lyu JY, Xu JG, Gu YD, Xu WD. Trial of Contralateral Seventh Cervical Nerve Transfer for Spastic Arm Paralysis. *N Engl J Med*. 2018 Jan 4;378(1):22-34. doi: 10.1056/NEJMoa1615208. Epub 2017 Dec 20. PMID: 29262271.



Jörg Bahm MD PhD

Chief: Brachial Plexus Surgery Unit, Plastic-, Hand- and Burn Surgery Clinic, University of Aachen, Aachen, Germany.
tel.: +49 (0) 241 8089702
email: jbahm@ukaachen.de

EDITOR: I HAVE ALWAYS WONDERED HOW THE BRAIN KNOWS WHAT TO DO WHEN WE SWITCH NERVES AROUND OR ATTACH THEM TO OTHERS. IS IT THAT THE PERIPHERAL SENSORY ORGANS SEND AREA SPECIFIC SIGNALS (LIKE MOBILE PHONES) BACK TO THE BRAIN, REGARDLESS HOW THE IMPULSES AND BY WHAT ROUTE THEY TRAVEL? THE BRAIN WILL ONLY RECOGNIZE (LIKE A MOBILE PHONE) THE PREDETERMINED SIGNAL AND RECOGNIZE ITS ORIGIN. SIMILARLY WITH MOTOR ACTIVATION. THE BRAIN SENDS AN INTENDED SIGNAL FOR A SPECIFIC MOVEMENT, AND THE NECESSARY INNERVATED AND/OR AVAILABLE MUSCLES WILL RESPOND. THIS COULD EXPLAIN HOW EG. ELBOW FLEXION WORKS WHEN INTERCOSTAL NERVES ARE USED TO MOTORIZED THE BICEPS. IT IS ALL ABOUT "THE ABILITY TO DO", RATHER THE FUNCTION OF THE NAMED MUSCLE OR NERVE! ULRICH MENNEN

Lessons learned from 25 years of replantation surgery

Since the first successful repair of an amputated arm in a 12-year old boy by Malt and McKhann in 1962⁽¹⁾, replantation surgery has become a common procedure for every hand surgeon and remains one of the most publicized parts of his discipline. Limb replantation has been the subject of more than 2500 scientific publications, with a current annual rate of more than 80. Nevertheless, a downward trend concerning both prevalence and success rates has been noticed within recent years by a lot of Authors, mainly in North America^(2,3,4). A number of reasons have been pointed out for this downward trend ; decentralization of replants from high-volume hospitals, paucity of on-call hand specialists, rising health care costs, decreasing reimbursement for replants, waning surgeon experience, increased selectivity of patients or fewer amputations.⁽²⁾

According to Billington et al.⁽⁴⁾, a contributing factor to lower replantation success rate could be the relatively high resident/fellow involvement in a surgical procedure with a notably high time requirement for proficiency. According to Hustedt et al.⁽³⁾, an amputation injury presenting to a high-volume surgeon (5 cases/year) at a high-volume center (20 cases/year) has a 2.5 times greater likelihood of obtaining a successful replantation than an amputation injury presenting to a low-volume surgeon at a low-volume hospital. In other words, experience remains one of the main keys of successful replantation surgery.

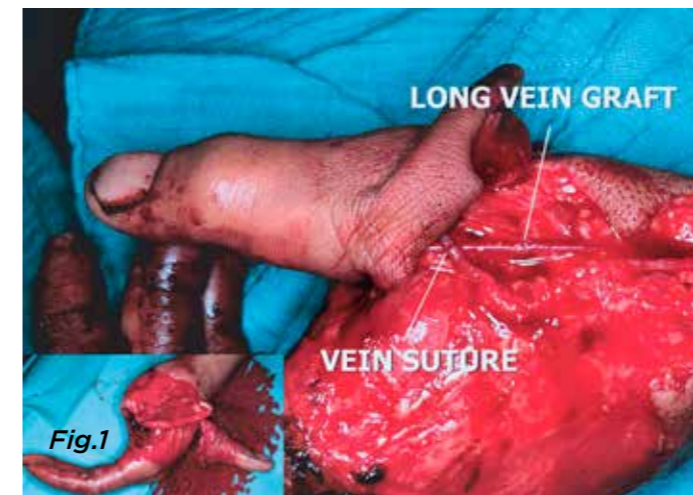
Even if it won't replace microsurgical training, sharing this experience might be helpful for any hand surgeon eager to improve his skills in replantation surgery. The following paper is primarily intended for them.

My colleague Patrick Suttor and I have been working together in the same Hand Unit in Belgium since 1997. Within 25 years, the volume of replantation cases we had to treat might not reach half of the cases reported by Alicia Billington's center. Nevertheless, we might be considered as experienced microsurgeons, I mean the ones Hustedt⁽³⁾ calls « high volume surgeons », and, not least, all our replantation cases were exclusively managed by ourselves. The area covered by our Hand center might not be the largest but within 25 years of time it has been busy enough for us to treat any kind of indications.

Hereunder we'll report the story of a few selected cases we had to treat and the lessons we learned from each of them.

The first case we wanted to report was a young male patient referred to us with a typical case of thumb avulsion. We were working together on that day and thank goodness, because it was one of our longest operating times, nearly 8 hours of surgery, mainly because of arterial problems. According to the aspect of the ulnar artery and despite the avulsion, we first tried a resection and direct suture, but it failed quickly so we switched to vein grafts, a short one first,

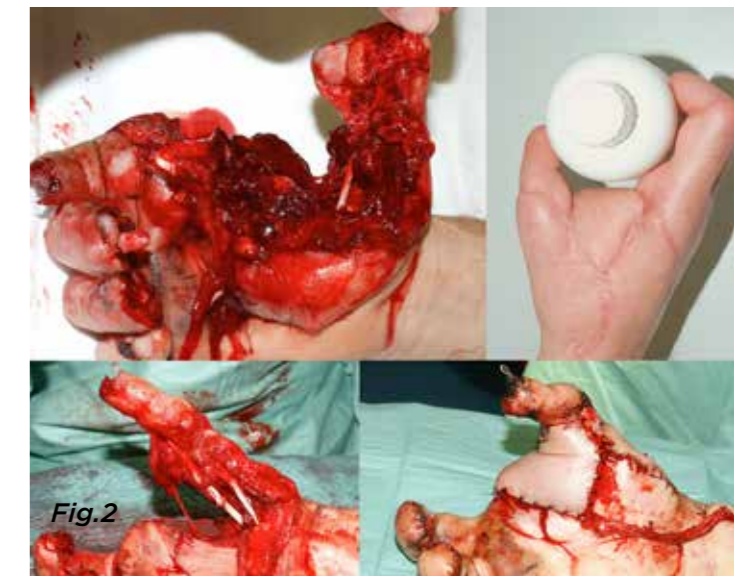which failed as well, a second one a bit longer without success and finally a very long one from the snuffbox to the IP joint and only at that stage the thumb was revascularized (Fig.1), with a very good cosmetic and functional result at the end.



So the first lesson we would like to share is perseverance. And this lesson is already written in the history books of microvascular surgery by a man named Harry Buncke, who was the first one to report a successful replantation of a rabbit ear in 1964. It was the first report of a successful repair of blood vessels of 1 mm in size, something that everybody thought to be technically impossible at that time. As interesting were the conditions under which his experiments were done ; they were done in his garage with his wife Constance as assistant because he had no access to any lab in his hospital. And even more revealing is that this experiment was attempted 51 times before it was successful⁽⁵⁾.

The second lesson we learned from that case is also something written a long time ago by some pioneers of microvascular surgery like Bernard O'Brien⁽⁶⁾ : in avulsion cases, the operating microscope already lets see a nice vessel wall about 8 mm from the rupture site, but the electron microscope can still show some significant lesions up to 4 cm. So except in very cleancut amputations, always resect a bit « more » of artery before anastomosis.

The following case we would like to share is a very peculiar one. It was a blast injury of the right hand in a right handed manual worker, with loss of thenar muscles and distal thumb, but also a subtotal amputation of the index finger, the only structure in continuity being the ulnar digital nerve... So that was a perfect case for an heterotopic replantation of the index finger on the thumb, with a long vein graft (remember lesson 2). In the same time, the flexor digitorum profundus tendon of the index finger was sutured to the flexor pollicis longus, an opposition transfer was done with the extensor indicis proprius and the first web was covered with a pedicle chinese flap (Fig.2). The early functional result was quite encouraging. The patient seemed as happy as we were. Nonetheless, he disappeared from sight for months and the next time we heard from him was in the T.V. news. He went completely crazy and one day he threatened to to bomb his house and to kill his family. Fortunately within a few hours he was overpowered by the police. And I felt quite uncomfortable with that story. I felt a bit guilty, guilty of something I always wanted to avoid, and this thing is counter-Darwinism⁽⁷⁾.

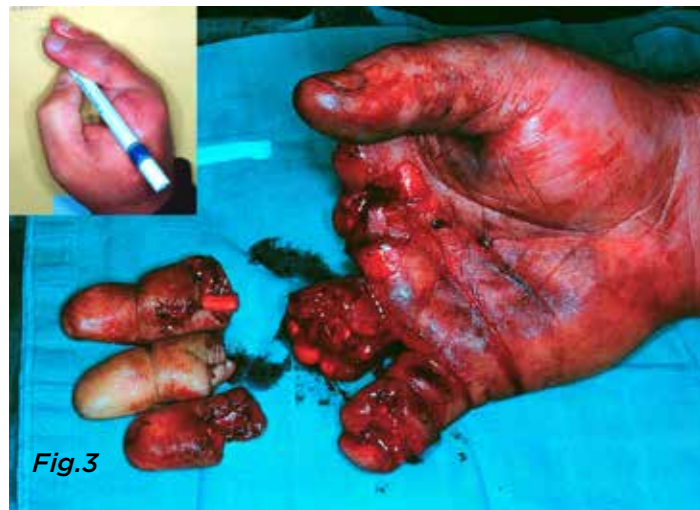

So lesson 3 : beware of the patient's psychological background. These kind of bad injuries do not happen randomly. These patients might be mentally unstable before the accident, and this instability can contribute to those kinds of injuries.

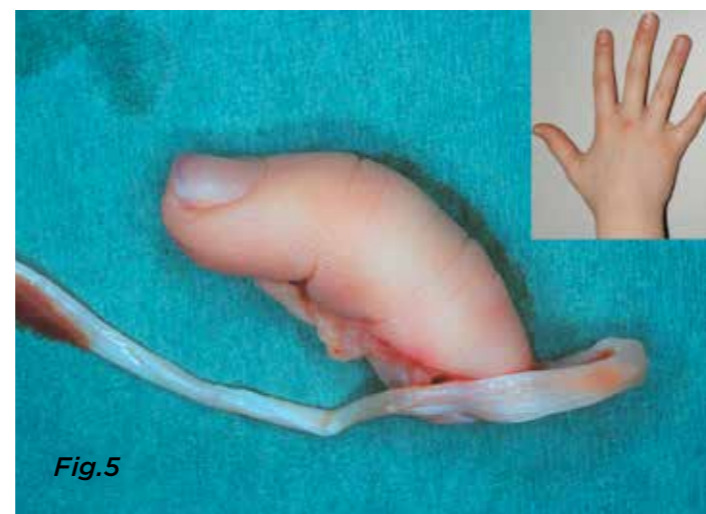
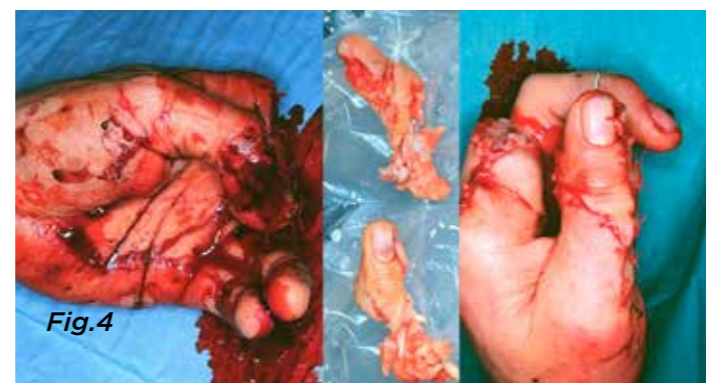And on the other hand those kinds of injuries can contribute to mental problems. In this respect, a good functional result might become a psycho-social disaster.

Anyway I haven't finished yet with this case. A few months later, his wife came to my clinic and said to me : « You know what Doctor ? My husband hanged himself, ank I have to thank you because you did a good job : the knot was very tight ! » The only answer which came to me was : « My pleasure ! ». But lesson 4 came to me as a relief just afterwards : Darwin was obviously right ⁽⁷⁾.

The next case was another bad lesion in a young independent right handed carpenter. Four fingers of the right hand were removed by a circular saw, with only three available for reconstruction and with 2nd and 3rd MP joints destroyed. What we did here is an heterotopic replantation from the third finger on the fourth ray and from the index finger on the fifth. And what still amazes me now about this patient was his speed of recovery. At about 9 weeks, he had already recovered a good grasp, a good pinch and even a good handwriting (Fig.3). This patient went back to work as a carpenter one week later, while at the same time, an administrative worker would still ask to be out of work because of pillar pain after carpal tunnel release. So remember lesson 4 and move to the next one : part of the success is clearly in the patient's head.



In another case of multiple finger injury, a carpenter lost more than half of his thumb and nearly the whole index and middle fingers, but with a spindle moulder, which is far worse than a circular saw, because the amputated fragments are usually so badly damaged that they are not suitable for replantation. The main problem here was to restore the full length of the thumb to regain a functional pollicidigital pinch with the ulnar fingers. In this case the emergency doctor came to us and said : « No hurry ! The amputated fragments are unsuitable for replantation. They are already in the trashbin. ». As soon as he turned his back, I went to the emergency unit, opened the trashbin, and I found exactly what I needed for an heterotopic replantation (Fig.4). The pollicidigital pinch was excellent at three months. From there, lesson 6 would be a reminder of a well-known principle in replantation surgery ; really all the means are good to preserve thumb length, and check the trashbin first before the patient's toes !

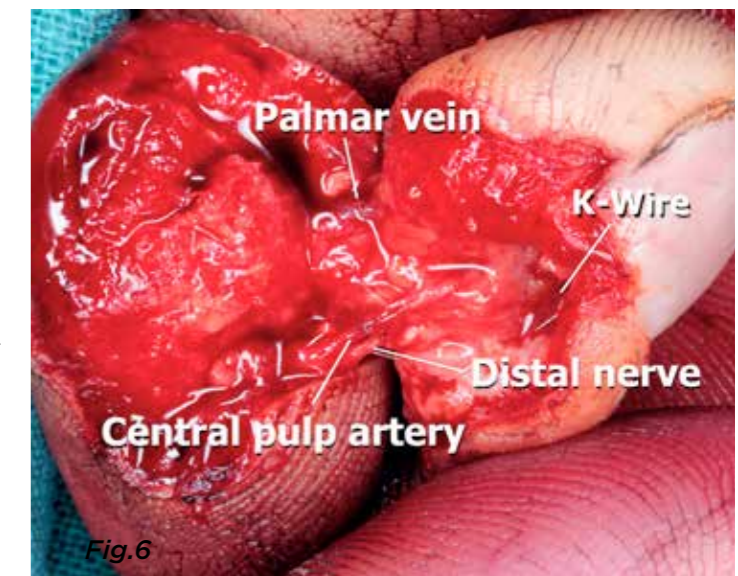


Single and proximal amputations of fingers are considered as contraindications for replantation, but there are some exceptions to that rule, especially in children. We also had to treat a rather rare case of complete avulsion of the fifth finger in a three years old child above the PIP joint level (Fig.5). The finger was trapped between two steps of a staircase and the rescuers had to dismantle the staircase to retrieve the amputated finger.

The replantation included the harvesting of a 15 mm vein graft to repair the ulnar digital artery (remember lesson 2). But what is quite interesting here is that we had the opportunity to see the patient about ten years later for another reason, and the patient was kind enough to let us check her fifth finger. Even if the PIP joint was stiff, she had good active flexion of the DIP joint, but the most surprising was the assessment of sensitivity. Two-point discrimination was near normal, Semmes-Weinstein was normal, wrinkle test was normal, and even sensibility threshold to vibrations or electrical stimulation were found to be normal. That is quite interesting because at the time of injury, the avulsion was so bad that both digital nerves were unable to be repaired. Spontaneous neurotization and sensory recovery in denervated flaps is something well reported, specially in oropharyngeal reconstruction, where 2pd can reach up to 6 mm ⁽⁸⁾. In the field of hand surgery, fingertip replantation without nerve repair can lead to even better results, and specially in children ⁽⁹⁾, but there is no data available in the scientific literature for proximal lesions above the PIP joint like here ⁽¹⁰⁾. Spontaneous neurotization is something not well explained and not fully understood. But what is clear is that the Meissner's Corpuscles are the main receptors responsible for fine discriminative touch and they do not disappear when the skin is denervated, so reconnection of these receptors is one of the keys ⁽¹¹⁾. But most probably the main key, able to explain these good results in children, is the brain synaptic plasticity. Lundborg himself says that the outcome of nerve repair depends mainly on central nervous system ⁽¹²⁾. So remember lesson 5 : part of

the success is in the head, but also, and it will be lesson 7 : replantation in children can pay off beyond expectations. . .

Lets move now to distal and very distal replantations, which have become the most frequent now, but which can be also very difficult and technically demanding. Some years ago ⁽¹³⁾, I had the opportunity to share our own experience of a dorsal approach for fingertip replantations (Fig. 6) with a series of 9 consecutive patients admitted to our emergency unit during a two year period with 11 fingertip amputations (thumb excepted) with a mean follow-up of of 18 months and a survival rate of 72.7 %. The main advantages of this approach is to avoid additional incisions, to have a mirror view of the section and find vessels and nerves more easily during dissection and to reduce the need of interpositional arterial or vein grafts without compromise on the survival rate. But beyond that, we would like to share two more lessons or two advices for those who are not used to distal replantations.



The first advice is about tremors, I mean the physiological tremors when you hold a position against gravity. You barely see it when you are suturing big vessels, but at high or very high magnification it might be a nightmare. So one of the most important phases of fingertip replantation is not during the anastomosis,

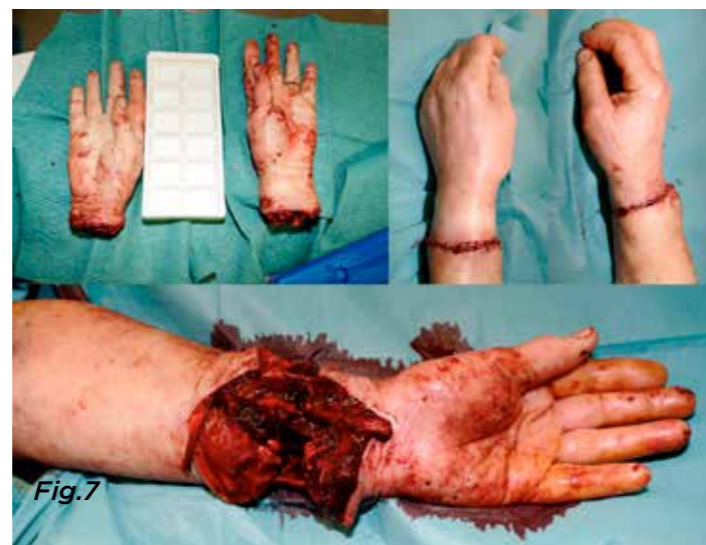but before the anastomosis. And it is stabilization ; stabilisation of the surgeon, straight position with the center of gravity in the middle of the stool, eyes and ocular at same level , and most of all support of the hands and forearms as distal as possible, stabilization of the patient's hand, mainly with fingertraps or lead hand, and stabilization of the fingertip itself, and that is another advantage of the dorsal approach because you will first stitch the volar skin, and you can even use the K-wires to support the distal fragment.

So lesson 8 would be that installation might be time-consuming but it is definitely time well spent... Vasospasm is also typical of fingertip replacements. It is very common and it can last for a very long time. In some of our cases, recolouration time was beyond 10 minutes. So lesson 9 : be patient ! do not go back too quickly to your sutures ; vasospasm remains the first reason for the absence of recolouration, and for a long time.

And finally let's share a few comments about a very rare case of double amputation at the forearm level we had to treat in 2019 (Fig.7). Very rare indeed because there are only about 7 successful cases reported in the world, including one in Brussels by Louis Kinnen and Jean Pierre Moermans. So rare that when we were called by the emergency unit, we really thought it was a bad joke... 68 years old man, suicide attempt with a circular saw...Do you remember lesson 3 ? The amputation level was just above the wrist on the right side and on the distal quarter of the forearm on the left. Replantation was done simultaneously: Patrick on one side and me on the other. Osteosynthesis was made with plate and screws on both sides, with an additional Darrach procedure on the right. Both radial and ulnar arteries were sutured and revascularization of both hands was reached between 3 and 4 hours and after the injury.

The whole procedure took us between 7 and 8 hours, the main problem being the fact that there was only one microscope available and we had to share it and

synchronize every step of the procedure without fighting against each other. Postop was uneventful. Revision surgery was done after 7 months on the right side, mainly tenolysis of extensor and flexor tendons and TM and CMC joint arthrodesis to open the first web space. Tenolysis of flexor tendons was done on the left side a few months afterwards, with a final extrinsic function quite honourable on both sides.



At the end, what did we learn from that case ? I would say from a technical point of view : nothing special. The key to success is to be found somewhere else and it is very simple. It is team working. From the mobile emergency care unit which preserved and cooled the amputated parts in a perfect way, but also chose the closest and most adapted hospital available, experienced nurses and anesthesiologist able to put the patient on the operating table to be operated so quickly, complicity between surgeons, accurate monitoring in the ICU and last but not least a really devoted physiotherapist. So the last lesson we would like to share here is a quotation borrowed from Rudyard Kipling's Jungle book : « For the strength of the Pack is the Wolf and the strength of the Wolf is the Pack ».

Bibliography

1. Malt R, McKhann C. Replantation of severed arms. JAMA 1964 ; 189 : 114-20.
2. Solaja O, Retrouvey H, Baltzer H. 2020. Trends in Digital Replantation : 10 Years of experience at a large canadian tertiary care center. Plastic Surgery. 2021 ; 29(1) : 21-29.
3. Hustedt JW, Bohl DD, Champagne L. The detrimental effect of decentralization in digital replantation in the United States : 15 years of evidence fom the National Inpatient Sample. J Hand Surg (Am). 2016 ; 41(5) : 593-601.
4. Billington, AR, Ogden BW, Le NK, King KS., Rotatori RM, Kim RL., Nydick J. A 17-Year experience in hand and digit replantation at an academic center. Plast Reconstr Surg. 2021 ; 148 (4) : 816-824.
5. Chase RA. In Memoriam : Harry J. Buncke, MD July 16, 1922-May 18, 2008. J Hand Surg (Am). 2008 ; 33(7) : 1245.
6. Mitchell GM, Morrison WA, Papadopoulos O, O'Brien BMcC. A study of the extent and pathology of experimental avulsion injury in rabbit arteries and veins. Br J Plast Surg. 1985 ; 38(2) : 278-287.
7. Darwin C. The origin of species by means of natural selection, or the preservation of favoured races in the struggle for life. Sixth edition, with additional corrections, John Murray Ed., Albemarle Street, London, 1872.
8. Netscher D, Armenta AH, Meade RA, Alford EL. Sensory recovery of innervated and non-innervated radial forearm free flaps : functional implications. J Reconstr Microsurg. 2000 ; 16(3) : 179-185.
9. Faivre S, Lim A, Dautel G, Duteille F, Merle M.

- Adjacent and spontaneous neurotization after distal digital replantation in children. Plast Reconstr Surg. 2003 ;111(1) :159-65.
10. Gilbert A. Discussion : Adjacent and spontaneous neurotization after distal digital replantation in children. Plast Reconstr Surg. 2003 ;111(1) :166.
 11. Wilson P, Snow PJ. Plasticity in the somatosensory system of developing and mature mammals - The effects of Injury to the central and peripheral nervous system. Springer Berlin/Heidelberg, 2011.
 12. Lundborg G. Brain plasticity and hand surgery : an overview. J Hand Surg (Br&Eur Vol). 2000 ; 25(3) : 242-252.
 13. Delaere O. Dorsal approach for fingertip replantation. Congress presentation. Les amputations traumatiques des membres, Lille, France, may 2004.
 14. Kipling R. The Jungle Book & The Second Jungle Book. Macmillan and Co, London, 1894.



O. DELAERE M.D. AND P. SUTTOR M.D.

Hand and Microsurgery Unit, Centre hospitalier Tubize-Nivelles, Rue Samiette, 1, 1400 Nivelles, Belgium

COMMENTS FROM DEPUTY EDITOR: THIS IS A DELIGHTFUL ARTICLE. IT IS FULL OF PRACTICAL DIRECTIONS AND WRITTEN WITH A EUROPEAN FLAIR. IN SHORT, IT IS FULL OF COMMON SENSE. MAY I COMPLIMENT THE SURGEONS/AUTHORS AND THANK THEM FOR BRINGING A SMILE TO MY FACE IN MEMORY OF PAST PROBLEMS ENCOUNTERED IN MANAGING THESE DIFFICULT CASES. SPECIFICALLY, I REMEMBER REPLANTING A LIMB AT FOREARM LEVEL AFTER THE PATIENT PLACED IT ON A RAILWAY TRACK IN FRONT OF AN ONCOMING TRAIN, AS THE PART(HAND) HAD OFFENDED HIM AND GOD. POST-OPERATIVELY, HE TOLD ME THAT HE MAY DO IT AGAIN. "AND I WILL REPLANT IT AGAIN", I RESPONDED, "WE WILL SEE WHO WINS". HE WAS QUITE MAD, OF COURSE, SIMILAR TO THE AUTHORS' PATIENT, BUT ALSO QUITE APPRECIATIVE OF MY WORDS. I PROBABLY SHOULDN'T HAVE SPOKEN THEM BUT HE SAID THAT HE WOULD GIVE THEM CONSIDERATION. MICHAEL TONKIN

Member Society

KOREAN SOCIETY FOR SURGERY OF THE HAND

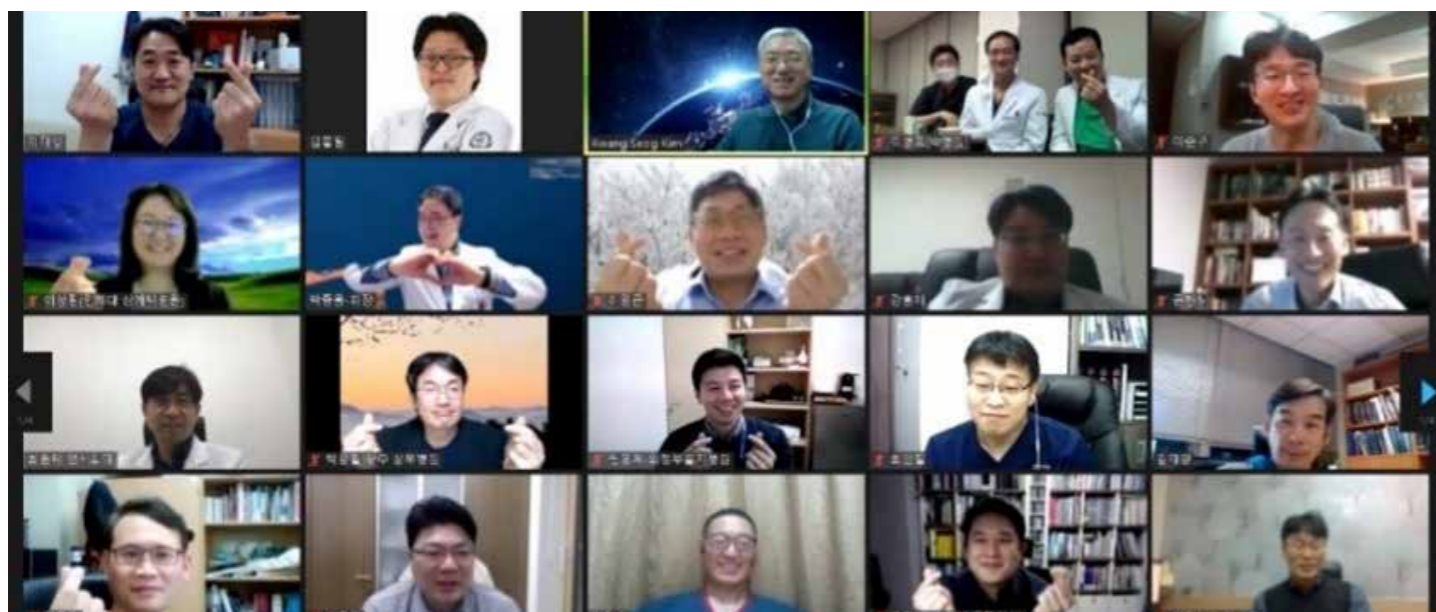During the last 2 years, members of the Korean Society for Surgery of the Hand (KSSH) have also suffered from the impact of COVID 19, and many local in-person meetings were cancelled. As we wanted to see each other at least online, we held six small webinar case symposiums bimonthly, each with a few case presenters and panelists. The topics were: "TFCC injury: controversies and challenges", "Treatment of contractures: principles and strategy", "Up-to-date knowledge of treatment of crush injuries", "My choice to improve functional recovery of the extremity", "Hand and wrist arthritis", and "Geriatric hand". To our surprise, the attendees were more than we expected, which reflected our members' desire to learn new knowledge and share their experience in hand surgery, as well as being eager to see the faces of their friends.

We found this platform was welcomed very much by

many young members who appreciate family life and want to save the time and energy required for in-person meetings.

Like other academic societies, we also held the 2021 annual congress of the Korean Society for Surgery of the Hand (KSSH) in online and offline hybrid form on 5-6 November 2021. At this meeting, we launched a new program called "Young Investigator's Camp", in which junior hand surgeons pursuing academic degrees have a chance to present their theses and get feedbacks from senior researchers.

We also had the honour to hear from two of our past presidents: Dr. Seok-Whan Song spoke about his path as a hand surgeon and scientist under the title "Hand Surgeon", and Dr. Jong-Ik Hwang talked about the role of hand surgeons and their patients in modern Korea, focusing on young workers who had their hands injured in factories during the time of rapid industrialization.



Photograph of the 1st KSSH Webinar symposium in 2021.

BELGIAN SOCIETY FOR SURGERY OF THE HAND

Second cycle of the Belgian Hand Surgery Certificate
The Belgian Hand Group (BHG) proudly announces that 20 young hand surgeons obtained the Belgian Hand Surgery Certificate (BHSC) on 18 June 2022. This 2-year inter-university training jointly organized by 7 Belgian universities teaches selected students the basics of hand surgery with theoretic and cadaver courses in 8 separate 2-day modules. Besides broadening their hand surgery knowledge, this education helps to prepare the students for the European Diploma in Hand Surgery examination later in their careers. The BHSC is open to orthopedic, plastic and general surgeons or residents (preferably in their last 2 years of training) or during their hand surgery fellowship training.



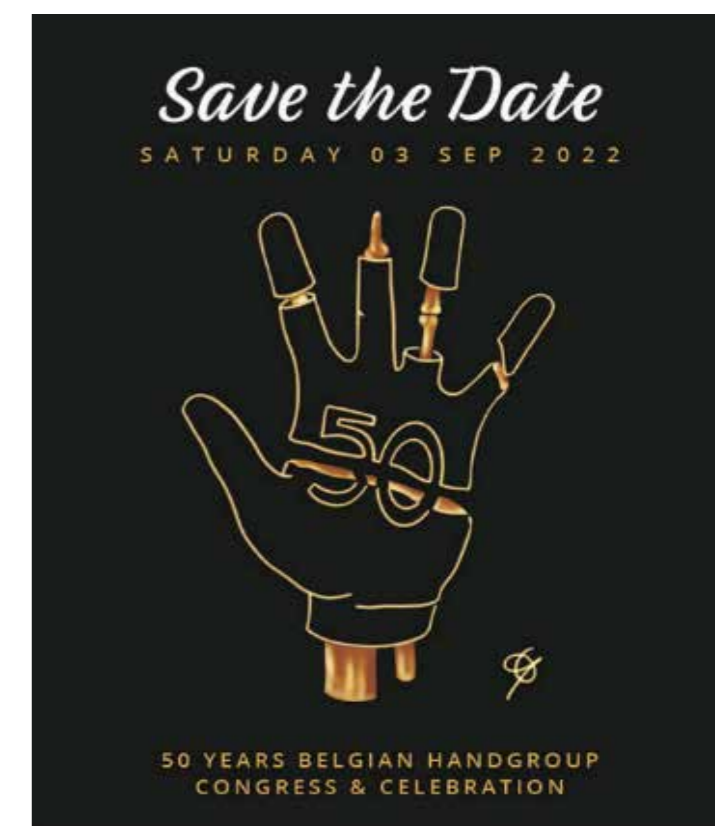
The 20 students fulfilled all requirements (attendance, examination and paper presentation). Due to COVID 19, some modules needed to be organized online or hybrid and cadaveric trainings had to be rearranged. However, the dual jury exam was live on the hottest day of the year! With the support of our research and education center (IORT), we managed to assess 26 candidates with 19 examiners in 6 juries. After the examination, the successful candidates were announced followed by a celebration in the blissful sun at Leuven University. Bram Van Hove achieved the highest grade on the oral exam and was offered the registration fee of the next FESSH meeting. He also received the best paper award and was invited to present his work at the 50th year Celebration Congress of the BHG on 3 September 2022. We were pleased that the majority of the students demonstrated a profound knowledge of hand surgery,

which is exactly the intention of the BHSC course. We are pleased to contribute to a higher level of quality of these future hand surgeons and hope that most of the candidates will further their hand surgery careers with a successful European Diploma in Hand Surgery. The BHSC continues to implement the positive feedback to improve the quality and the interactive teaching. We are grateful for all the participants who made this course successful for their voluntary and dedicated work.

50 year anniversary of the Belgian Hand Group
We are proud to celebrate the 50th anniversary of our scientific and professional hand surgery organisation, the BHG, and look forward to the Celebration Congress on 3 September 2022.

Next cycle of the BHSC: 2022-2024

More information at <https://www.bhsc.be/>
<https://belgianhandgroup.be>



Museum
Leuven

INFO: WWW.BELGIANHANDGROUP.BE

PERUVIAN ASSOCIATION OF HAND SURGERY AND MICROSURGERY

(Asociación Peruana de Cirugía de Mano y Microcirugía)(APCMM)

The Peruvian Association of Hand Surgery and Microsurgery was founded on 3 January 2014. It currently has almost 30 medical specialists dedicated to the exciting specialty devoted to the hand. Our current president is Mirko Tello Vinces M.D.

After many national and international activities, we are organising the "First National Congress of Hand Surgery in Peru", which will be held from 13-15 October 2022. More than 15 foreign exhibitors and 10 national exhibitors will participate in this event. A large turnout of doctors is expected.



Members of APCMM

The Congress program includes in addition to the presentations, a significant number of practical osteosynthesis workshops for the training of the participants. It also includes a theoretical-practical course on hand rehabilitation for Occupational Therapists.

We are proud to be part of the IFSSH family by contributing and promoting to the science and knowledge of the hand, and in fostering friendship and collaboration with colleagues from other countries.

We are welcoming you to join us in our first Congress in Peru!

Mirko Tello Vinces M.D.



Mirko Tello Vinces, Pedro J. Delgado, Jeffrey Yao



Second Hand Surgery Course

AUSTRIAN SOCIETY FOR SURGERY OF THE HAND

The Austrian Society for Surgery of the Hand held its Annual Meeting from 6-8 May 2022 in Graz, Styria, Austria. It was our second in-person Annual Congress since the start of the Corona pandemic. More than 200 hand surgeons and therapists participated sharing their knowledge. The main topic of the Congress was "Complex Regional Pain Syndrome – CRPS", and was divided into 5 key-notes presentations and six well-moderated sessions.

The aim and mission of the Austria Society is to stay abreast with the rapid scientific development and international standards in hand surgery. Therefore it is necessary to give high priority to education and training in the field of hand injuries and disorders to ensure an adequate quality of practice.

The Innsbruck University Hospital for Orthopaedic Surgery and Traumatology investigated the variation in patterns and volumes of injuries admitted to a level one trauma centre during lockdown for COVID-19. Due to the global COVID-19 pandemic, a ban on sports outside one's home and a prohibition on travel between communities were imposed in spring 2020 in Tyrol, Austria. The aim of this study was to evaluate the impact of these restrictions on a level one trauma centre. The objective was to identify the most common injury patterns to ensure optimal targeted prevention in the future in case of an ongoing pandemic. Among the injuries treated during the lockdown the largest increase in relative numbers was in home injuries to the head and face, and superficial or penetrating injuries. There was a decrease of serious injuries as well as patients who needed surgery during the lockdown compared to previous years. Since the study revealed a significant change in the pattern during the lockdown, intervention programs to reduce the risk of home injuries should be introduced. Furthermore, in order to save resources during a pandemic, specific guidelines on patient management and treatment

should be established for the respective medical specialties (these findings were published in: Journal of Orthopaedic Surgery and Research (2022) 17:306)

In 2018 the Forum of Young Surgeons was founded with the aim to establish an international network of young surgeons and to organize further education and training. The forum has their own session at the Annual Meetings and is about to organise a scientific meeting in the upcoming autumn to deepen personal contacts, knowledge, and experience.

Since 2020 the so called LEO Award is offered to the most innovative scientific publications in the field of hand surgery, and up to 2022, 8 young surgeons were awarded this prize for their scientific work.

At the highly successful 2022 IFSSH Congress in London, the Austrian Society was represented by 26 oral presentations and 4 e-posters covering a broad spectrum of scientific topics.

The next Annual Austrian Meeting will be hosted in Spring 2023 in Bad Ischl, a health resort near Salzburg and famous place of former Austrian royalties and composers.

Prim. Dr. Walpurga Lick-Schiffer Prof. - President
Dr. Rohit Arora - Austrian Delegate



"Prim. Dr. Walpurga Lick-Schiffer, President of the Austrian Society, with the LEO Award winners. The LEO Award is a prize which is awarded to young surgeons for innovative publications in the field of hand surgery."

ECUADORIAN SOCIETY FOR SURGERY OF THE HAND (ECUMANO)



“Hand Surgery United” in Latin-America

At the last IFSSH Congress in London in June 2022, the large number of participants from the

whole of Latin America have produced and presented numerous papers and presentations which indicates the increasing hand surgery activities in this region.

A total of 176 Hand Surgeons from 9 Latin American countries went to London to be part of this world meeting.



Latin-America is also proud to have for the first time two elected representatives on the Executive of the IFSSH. Representing North America is Dr. Jorge Clifton Correa from Mexico, who is a renowned brachial plexus and peripheral nerve surgeon, and on behalf of South America is the President of the Colombian Association of Hand Surgery Dr. Aida Garcia Gomez who brings much experience to the IFSSH Exco. All of Latin America congratulates the two representatives from this Continent, who have much to contribute.

Another important achievement for Latin America was that the Ecuadorian Society for Surgery of the Hand, ECUMANO, won the opportunity to organise the First Mid Term Course, a newly established educational initiative by the IFSSH. It will take place in the city of Guayaquil, Ecuador in February 2024, and will be jointly organised by representatives from all over our Continent. This effort will not only further unite hand surgery in South America, but will significantly help in growing our beautiful speciality.

The members of “Hand Surgery United” in Latin America extends a warm welcome to all our international colleagues to join us for this first IFSSH Mid Term Course in the very centre of our planet, Ecuador!



AUSTRALIAN SOCIETY FOR SURGERY OF THE HAND

The Australian Hand Surgery Society (AHSS) is celebrating its 50th year in 2022. The AHSS was formed initially in 1972 as the Australian Hand Club, with this group of enthusiasts growing to become the AHSS in 1990. The AHSS has grown to a membership of over 200 surgeons and now is responsible for the education programme for qualified orthopaedic, plastic and reconstructive, and general surgeons who wish to specialise further in hand surgery in Australia and New Zealand. The AHSS also supports research and further professional development with grants and travelling fellowships, and sponsors hand surgery outreach programmes to South-East Asia and the South Pacific. While the COVID pandemic restrictions limited the AHSS to an online meeting in 2021, we were able to return to a face-to-face scientific meeting earlier this year. In 2023, the AHSS will host the British Society for Surgery of the Hand at its annual meeting in Sydney and is joining with the American Society for Surgery of the Hand for a meeting in Hawaii in 2024.

The AHSS continues to be an active member of the IFSSH. Several AHSS members have been recognised as IFSSH pioneers of Hand Surgery with the most recent being Professor Michael Tonkin who was awarded this honour at the IFSSH meeting in London. The AHSS also supports the Asia-Pacific Federation of Societies for Surgery of the Hand (APFSSH) having hosted the most recent APFSSH meeting on the eve of the COVID pandemic in 2020 and is represented on the APFSSH executive by Anthony Berger, the President-elect. We are looking forward to participating in the APFSSH meeting in Singapore in 2023.

The AHSS continues to develop and in addition to its role in education and advocacy on behalf of its members, it is seeking to promote diversity within its membership and encourage the engagement of the younger members of the society with roles within the executive and its other portfolios of responsibility.



Professor Michael Tonkin, (Past President AHSS and IFSSH), was honoured as a Pioneer of Hand Surgery at the recent IFSSH meeting in London, 2022.

David McCombe

Clinical Associate Professor, University of Melbourne Plastic and Maxillofacial Surgery Dept, Royal Childrens Hospital, Melbourne

MEXICAN ASSOCIATION FOR SURGERY OF THE HAND

Asociación Mexicana De Cirugía de la Mano A.C. (AMCM)

Celebrating 40 years of Hand Surgery in Mexico

The Mexican Association for Surgery of the Hand is celebrating 40 years of existence. When it was founded in 1980 by a small group of plastic and orthopedic surgeons, the Association now has many Hand Surgeons around the country, and is actively engaged in training and continuing medical education. The 40 year celebration had to be postponed due to the Covid-19 pandemic.

Eventually, in February 2022, we had the celebrations at our 42nd anniversary in Mexico City. During this meeting a number of our Founders and Past Presidents were honoured by the current board members.

For this meeting we had the honour of having an international faculty from Spain, IFSSH President Dr. Marc García Elías and Dr Samuel Pajares, and Dr Alejandro Badia from USA.



The board of the AMCM left to right: Dr. Emmanuel Ruiz, Dr. Raquel Montes, Dr. Juan Ramon Bonfil (President) Dr. Jorge Luna, Dr. Victor Azpeitia (actual coordinator of altruistic surgery missions), Dr. Joaquin Díaz, Dr. García Velazco, Dr. Francisco García Lira, Dr. Juan Manuel Fernández Vázquez, Dr. Alfonso Vega, Dr. Nicolás Sastré, Dr. Sergio Funes Craviotto, and IFSSH President Dr Marc García-Elías



Board members of the Mexican Association with the international faculty.



Dr Marc García Elías lecturing on the biomechanics of the forearm.



Dr Samuel Pajares, Dr Joaquin Díaz, Dr Emmanuel Ruiz, Dr Marc García Elías and Dr Juan Ramon Bonfil during the faculty dinner after the meeting.

Mexican delegation at the Ibero-Latin American (ILA) Hand Surgery Meeting in Maceió, Brasil.

In March, the biannual Ibero-Latin-American (ILA) Hand Surgery Meeting took place in Maceió, Brasil and the organising committee invited Mexican surgeons as part of the international faculty. Our president Dr Juan Ramon Bonfil led the Mexican delegation and their contributions were outstanding. The AMCM expresses its appreciation to the Brazilian surgeons Dr. Raimundo Araujo and Dr Ricardo Kaempf for the invitation and congratulate them on a successful event. Thank you Maceió!



Board members of ILA, Dr. Raimundo Araujo, Dr. Ricardo Kaempf, Dr. Pedro Delgado and Dr. Juan Ramon Bonfil at the opening ceremony of the XIII ILA meeting in Maceió



Dr Juan Ramon Bonfil, President of AMCM,



Dr Salvador Magallon lecturing in Maceió



Dr Salvador Magallon lecturing in Maceió



Dr. Erika Ibañez on her talk about anatomy variants in carpal tunnel release.



Dr. Carla Orozco from the Mexican Association lecturing at the ILA meeting



Mexican and Ecuadorian surgeons at the ILA meeting in Maceió.

XII Annual Meeting of the Mexican Association for the Surgery of the Hand, Guadalajara Mexico.

In November 2022 the AMCM will be celebrating its XII Annual Hand Surgery Meeting which will take place in Guadalajara, Mexico. The faculty will be outstanding! Some of our international professors are: Dr. Pedro Delgado, Dr Martin Caloia, Dr René Jorquera, Dr. Andrea Atzei, Dr. Joaquim Casañas, Dr. Vicente Carratala, Dr. Aida García, Dr. Fidel Cayon, Dr. Jesse Jupiter, Dr. Michael Haussman, Dr. Matias Sala, Dr. Luis Felipe Naquira, Dr. Orlando Cruz, Dr Carlos Eduardo Saenz and Dr. Marc García- Elias.

See you in Guadalajara!

Guadalajara Jalisco
9, 10, 11 y 12 de noviembre 2022

Duodécimo Congreso Nacional de la Asociación Mexicana de Cirugía de la Mano A.C.

Hotel Hotsson Smart Autónoma Guadalajara

CANADIAN SOCIETY FOR SURGERY OF THE HAND (CSSH)

After a pandemic induced two-year hiatus, the Canadian Society for Surgery of the Hand (CSSH) was back to an in-person annual meeting, taking place on 14 June 2022. Old friends and colleagues were reunited at the beautiful Fairmount Château Frontenac in the historic old quarter of Québec City. A simultaneous virtual platform was also available for those unable to attend in person. The meeting involved a series of panel discussions from Canadian experts sharing tips and tricks, unique cases, and clinical wisdom. Both plastic surgery and orthopedic surgery trained speakers focused on topics including opioid prescribing practices in hand surgery, basal thumb joint osteoarthritis, ulnar-sided wrist pain, and nerve gap management. The hybrid format worked exceptionally well to stimulate many fruitful discussions and personal stories. There were over 90 attendees in-person, in addition to those attending virtually. It was wonderful to have so much participation from across the country!

The CSSH would like to congratulate Dr. Jessica Winter, graduating plastic surgery resident from the University of Manitoba, as the recipient of this year's CSSH Hand Surgery Scholarship! Dr. Winter will be going on to complete fellowship in Hand & Upper Extremity Surgery at the University of Kentucky before returning to Canada to pioneer a multidisciplinary hand surgery outreach program for residents of the northern territories.

The CSSH would also like to recognize the passing of the torch from Dr. Avi Islur (University of Manitoba) to Dr. Heather Baltzer (University of Toronto) as President of the Society. Our sincere appreciation to Dr. Islur for all the hard work he has done for the CSSH. Many thanks also to our Executive Committee and CSSH Board Members for all the hard work they put into organizing this year's conference.

We look forward to seeing everyone at next year's meeting in the picturesque Whistler, BC! Information on registration will be available on our website: <https://www.csshscm.com/>



CSSH members getting reacquainted at the conference in Quebec City.



CSSH members enjoying some refreshments and good company!



Outgoing CSSH President Dr. Avi Islur, new CSSH Vice President Dr. Dominique Tremblay and Past CSSH President Dr. Don Lalonde

BRAZILIAN SOCIETY FOR SURGERY OF THE HAND



We all had a good time at the 15th IFSSH Congress in London, enjoying the reunion with old friends and all the great experiences which London has to offer!

More than 60 Hand Surgeons from Brazil were in the delegation at the IFSSH meeting in London, 6-10 June 2022, with active participation in symposia, lectures and free papers.



We had the honour of having two more Brazilians "IFSSH Pioneers of Hand Surgery": Dr Ronaldo Jorge Azze and Dr José Mauricio de Moraes Carmo.



Dr. Ronaldo Jorge Azze



Dr. José Mauricio de Moraes Carmo

The Brazilian Society for Surgery of the Hand (SBCM) will have their 42nd annual meeting in Campinas from 4-6 August 2022 with many confirmed guest speakers from Brazil and other countries.

In November 2022, Brazil will participate as a guest nation at the ASSH meeting in Boston, where we will be attending again with a large delegation.



42° Congresso Brasileiro de Cirurgia da Mão

Centro de Convenções Expo D. Pedro
Campinas - São Paulo
04 a 06 de agosto de 2022

Dr. Samuel Ribak
President

Dr. Milton Bernardo Pignataro
Delegate

ASSOCIATION OF CHINESE-SPEAKING HAND SURGEONS UNITED (ACU)

Association of Chinese-speaking Hand Surgeons United (ACU) and 8th Jixia Hand Surgery Forum 2022

The 4th Congress of the Association of Chinese-speaking Hand Surgeons United (ACU) and the 8th Ji Xia Forum was held on the 25 and 26 June 2022, as an online event. The ACU Congress was attended by over 8674 online attendees (counted by login numbers), with program chairs Drs Jing Chen and You Mao Zhen under the ACU president Dr Sufeng Wang. The program consisted of symposiums, keynote lectures (one mid-career and one senior), free paper sections, educational courses, and round table discussions. The senior keynote lecture (30 minutes) was given by Dr Alain Gilbert entitled "50 years' experience of microsurgery and hand surgery".

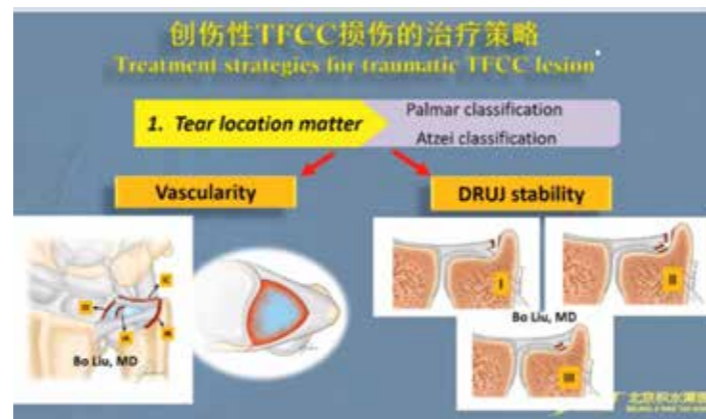
A variety of wrist conditions were discussed in the symposiums. Four instructional courses focused on wrist ligament repair, treatment of comminuted distal radius fracture, congenital hand deformities, and 3D printing of metacarpal and phalangeal bones. Nerve graft, evaluating methods of nerve regeneration, and the treatment of Kienbock's disease were discussed in round table discussions. In addition, the meeting of the ACU Therapists' Society was held together with ACU Congress to discuss relevant techniques in hand rehabilitation.

The 8th Jixia Forum of Hand Surgery in 2022, was attended by 7213 online colleagues (login numbers) (Figures are random screen shots of the presentations). This Forum was organised by Hand Surgery departments of four major hospitals from different parts of mainland China. Similar to the Forums in previous years, the discussions were very lively with a lot of debates on popular topics in hand surgery. This is a very attractive and popular way of interaction among Chinese-speaking hand surgeons from mainland

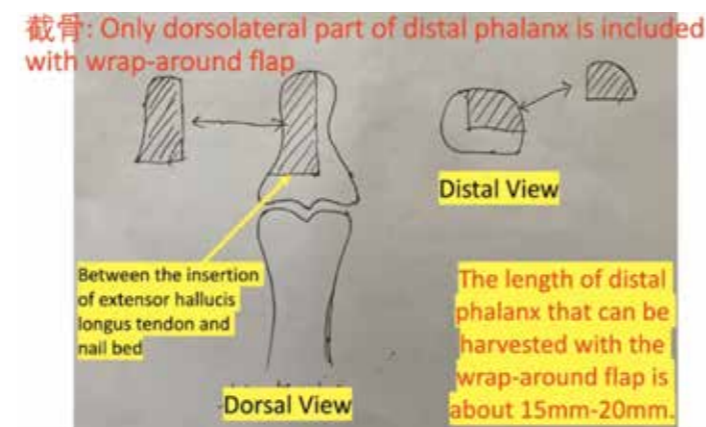
China, Taiwan and other regions in the world. These events are held annually in early summer. Our hope is that next year we will be able to return to the previous format of both on-site (in person) and online streaming.

ACU also regularly hosts the Nanshan Lecture Series jointly chaired by Drs Jin Bo Tang and Zeng Tao Wang, as well as Journal Clubs led by Drs Chao Chen and Yung-Cheng Chiu.

In the future ACU will add workshops and local seminars to expand its educational missions to different regions.



Two screenshots from presentations



Dr Jing Chen

email: moshengren1013@163.com



13TH APFSSH, 9TH APFSHT & 8TH APWA CONGRESS

DIVERSE & INCLUSIVE



ABSTRACT SUBMISSION NOW OPEN

SUBMISSION DEADLINE 20TH OCT 2022

31st May - 3rd June 2023, Singapore
www.apfssh2023.org



#APFSSH2023

1er CONGRESO NACIONAL DE CIRUGÍA DE MANO

APCMM
ASOCIACIÓN PERUANA DE CIRUGÍA DE MANO Y MICROCIROGÍA

SAVE THE DATE

13,14 y 15 de OCTUBRE 2022

Lima - Perú

INFORMES: apcmanomicro@gmail.com o al Celular: 956 621 905



2023 World Symposium on Congenital Malformations of the Hand and Upper Limb

Minneapolis, Minnesota, USA May 17-20, 2023

Abstract Submissions are open.

Be a Part of the Meeting

Abstract submissions are now open for the [2023 World Symposium on Congenital Malformations of the Hand and Upper Limb](#). We encourage you to participate in the meeting by submitting an abstract for a paper or poster presentation. The meeting will take place in the United States for the first time in over 10 years. We hope you will join us in Minneapolis, Minnesota, May 17-20, 2023. Registration will open in the fall.

Abstract submissions are due on August 31, 2022.

[Submit an Abstract](#)



[ASSH HOME](#) | [EDUCATION](#) | [HAND.E](#)

American Society for Surgery of the Hand
822 W Washington Blvd., Chicago IL 60607
Fax: (847) 384-1435 | Phone: (312) 880-1900 | Web: www.assh.org



42° Congresso Brasileiro de Cirurgia da Mão

Centro de Convenções Expo D. Pedro
Campinas - São Paulo
04 a 06 de agosto de 2022

SAVE the DATE

August 04th to 06th, 2022

Program Highlight

- Hand injuries in an elderly populations
- Nontraumatic disorders of the hand
- Flexor tendon injuries
- Walant

Register online:
www.mao2022.com.br/

EXECUTIVE SECRETARY AND SCIENTIFIC:



www.atepeventos.com.br

REALIZATION:



www.cirurgiadamao.org.br

SECRETARY COMMERCIAL:



www.sartorieventos.com.br

Will we see you in Sydney? or virtually?

ahta.com.au/conference | enquire@ahta.com.au



— TRAUMA —
HAND | BRAIN | PERSON
2022 AHTA CONFERENCE
SYDNEY 25-28 AUGUST





[» Register Now](#)

Reminders:

- ✓ Add a Pre or Postcourse
- ✓ Mark your calendar for HANDAPALOOZA.
- ✓ Book your hotel room.
- ✓ Make plans with your colleagues.



Join your colleagues in Boston for the 2022 in-person Annual Meeting

We are thrilled to be back to an in-person meeting in 2022 and we hope that you will be a part of it. Our Chairs, R. Glenn Gaston, MD and Peter C. Rhee, DO, MS have an exciting program planned that you will not want to miss.



[» Register Now](#)

Reminders:

- ✓ Add a Pre or Postcourse
- ✓ Mark your calendar for HANDAPALOOZA.
- ✓ Book your hotel room.
- ✓ Make plans with your colleagues.




[ASSH HOME](#) | [AFSH HOME](#)

American Society for Surgery of the Hand
 822 W Washington Blvd., Chicago IL 60607
 Fax: (847) 384-1435 | Phone: (312) 880-1900 | Web: www.assh.org

